

Evaluation of Solitary Thyroid Nodule

Passos ID^{1*}, Pliakou E² and Mironidou- Tzouveleki Maria³

¹General Surgery Resident, PhD Candidate, A' Laboratory of Pharmacology, Faculty of Medicine, School of Health Sciences, Aristotle University of Thessaloniki, Greece

²Medical Oncology Resident, PhD Candidate, B' Laboratory of Pharmacology, Faculty of Medicine, School of Health Sciences, Aristotle University of Thessaloniki, Greece

³Anesthesiologist, Professor of Pharmacology, A' Laboratory of Pharmacology, Faculty of Medicine, School of Health Sciences, Aristotle University of Thessaloniki, Greece

***Corresponding author:** Passos ID, General Surgery Resident, A' Laboratory of Pharmacology, Aristotle University of Thessaloniki, Greece, Email: ioannispassos@gmail.com

Published Date: August 02, 2016

OVERVIEW

Nodular disorders of the thyroid gland are relatively common among adults living in the United States, with an overall prevalence of approximately 4-7% in the general population. Most thyroid nodules are benign hyperplastic lesions, but 5-20% of thyroid nodules are true neoplasms. (A retrospective study by Keh et al of 61 patients found 75.4% of solitary thyroid nodules to have a neoplastic pathology and 34.4% to be malignant [1]).

One of the major goals in the evaluation of the solitary thyroid nodule is the differentiation of hyperplasia from true neoplasms. Furthermore, the histologic criteria used to distinguish benign from malignant neoplasms can be subtle. Evaluation of solitary thyroid nodules requires the collaboration of the primary care physician, endocrinologist, pathologist, radiologist, and head and neck surgeon to provide comprehensive and appropriate management of this clinical entity.

Solitary thyroid nodule may represent a multitude of thyroid disorders, and a thorough knowledge of the epidemiology of thyroid disease is of paramount importance. Medical history and physical examination of the patient adds significantly to the determination of the nature of the thyroid nodule. Currently, a variety of serologic and cytogenetic tests, diagnostic imaging studies, and histopathologic techniques exist for the evaluation of a thyroid nodule. Of these methods, Fine-Needle Aspiration Biopsy (**FNAB**) has become the most important tool in the assessment of solitary thyroid nodules.

The prevalence of thyroid nodules within a given population depends on a variety of factors that include age, sex, diet, iodine deficiency, and therapeutic and environmental radiation exposure. Thyroid nodules are found in approximately 1.5% of children and adolescents. They are more common in females, and this predisposition exists throughout all age groups. In fact, palpable nodular disease is 6 times more common in adolescent females compared to males of the same age.

Thyroid nodules are more common in women than in men. Prevalence increases with age, with spontaneous nodules occurring at a rate of 0.08% per year beginning early in life and extending into the eighth decade. Thyroid nodules are found in 5% of persons aged an average of 60 years.

Exposure of the head and neck to ionizing radiation increases the incidence of thyroid nodules. Radiation treatments were not uncommon in the first half of the twentieth century for benign conditions such as acne, adenotonsillar hypertrophy, and enlarged thymus glands. The prevalence rate of thyroid nodules in radiation-exposed patients increases significantly, ie, 16-31% relative to the general population. A direct dose-response relationship between thyroid nodularity and radiation to the head and neck region also exists.

DIFFERENTIAL DIAGNOSIS

Many thyroid diseases can manifest clinically as solitary thyroid nodule. The differential diagnosis of solitary thyroid nodule can be broadly classified into benign and malignant. Parameters for cytologic assessment of solitary nodules include (1) cellularity, (2) colloid content, (3) acinar formation, (4) papillary formation, (5) intranuclear cytoplasmic inclusions, (6) nuclear grooves, (7) marginal vacuoles, (8) Hürthle cells, (9) presence of various inflammatory cells, and (10) cellular atypia. The presence or absence of signs and symptoms of altered metabolic function can help establish the correct diagnosis. Generally, most thyroid nodules are benign and can be classified as adenomas, colloid nodules, congenital abnormalities, cysts, infectious nodules, lymphocytic or granulomatous nodules, or hyperplasia.

BENIGN THYROID NODULES

Thyroid Adenomas

Thyroid adenomas are benign neoplasms, which are usually classified as follicular or papillary.

Follicular adenomas are the most common type of adenomas and arise from the follicular epithelium within the thyroid gland. They are typically homogeneous, solitary, and encapsulated tumors that are histologically distinct from adjacent thyroid tissue. Follicular adenomas are further classified according to their cellular architecture and relative amounts of cellularity and colloid into fetal (micro follicular), colloid (macro follicular), embryonal (atypical), and Hürthle (oxyphil) cell types. Colloid adenomas do not have any potential for micro invasion, while the fetal, embryonal, and Hürthle cell adenomas all have the potential for micro invasion. Papillary adenomas are the least common type of thyroid adenoma.

Hyperplastic Nodules

Hyperplastic nodules can be differentiated from colloid goiters by the presence of excessive cellularity, acinar formation, marginal vacuoles, papillary formation, and the amount of colloid present in the specimen. Neoplasms have a higher degree of papillary formation, intranuclear inclusions and nuclear grooves, and fewer marginal vacuoles. Congenital thyroid nodules include congenital hemangioma, thyroglossal duct anomalies, and familial disorders, such as Multiple Endocrine Neoplasia (**MEN**) syndromes and congenital goitrous hypothyroidism.

Thyroid Cysts

Thyroid cysts represent 15-25% of all thyroid nodules and are usually diagnosed by the aspiration of fluid from a solitary thyroid nodule. These entities are often caused by cystic degeneration of normal thyroid tissue, hemorrhage or trauma, occult follicular adenoma or carcinoma, multinodular goiter, or branchial anomalies that involve the thyroid gland. Simple epithelium-lined cysts, hemorrhagic colloid nodules, or necrotic papillary thyroid cancers can be found in resection specimens. In one particular study, 68% of cystic thyroid lesions selected for surgical therapy were benign, while 32% were thyroid carcinomas. To improve the diagnostic accuracy of aspiration biopsy, some authors advocate biochemical analysis of cyst fluid.

Thyroiditis

Diagnosis of thyroiditis includes 5 disorders. Hashimoto thyroiditis is an autoimmune disease; principal manifestations are goiter and hypothyroidism. Sub acute granulomatous thyroiditis is probably viral in origin, and patients usually present with a tender goiter. Sub acute lymphocytic thyroiditis is of unknown pathogenesis, but the postpartum form may be autoimmune. Its principal manifestations are goiter and spontaneously reversible hyperthyroidism. Acute superlative thyroiditis results from bacterial or fungal infection causing abscess. Riedel struma, a disease of unknown cause, manifests with a goiter and thoracic inlet obstruction. The presence of clinical or metabolic hyperthyroidism in combination with painful nodular thyroid disease strongly suggests thyroiditis as a potential diagnosis. Local abscess is usually infectious, but it may develop from necrotic undifferentiated thyroid carcinoma. Infectious etiologies include bacterial, viral, fungal, and parasitic sources, or it could be the result of perform sinus fistula.

Malignant Thyroid Nodules

Thyroid carcinoma represents approximately 1% of all new cancers reported in the United States (about 12,000/y) and 92% of all endocrine gland cancers. Despite the low number of clinically evident cases, incidence of occult thyroid carcinoma has been reported in the range of 4.2-10% of all autopsy specimens. Variation in the incidence of autopsy cases depends on the study population, method of examination, and prior radiation exposure. Discrepancy between occult and reported cases of thyroid cancer suggests significant variations in screening and biologic behavior of the tumor. Additionally, the relatively high incidence of occult thyroid cancer at autopsy may imply a benign clinical course. Despite these facts, death due to uncontrolled local, regional, and distant disease can occur from thyroid cancer, and appropriate management is important in these cases.

The sex and age of the patient appear to play an important role in the clinical outcome of patients with malignant neoplasms of the thyroid gland. Although solitary thyroid nodules are found more frequently in women, incidence of carcinoma in solitary thyroid nodules is increased in men. Several studies have reported a bimodal age distribution of thyroid carcinoma in solitary thyroid nodules. Reported prevalence of thyroid carcinoma in an asymptomatic nodule is 3.4-29%. Data in medical literature are conflicting regarding increased prevalence of thyroid carcinoma in solitary nodules in the elderly population.

History of prior radiation exposure is an important risk factor for thyroid carcinoma. The risk of developing thyroid carcinoma increases following radiation exposure and is dose-dependent. Data collected from large populations intentionally or accidentally exposed to radioactive material have established a clear relationship between radiation exposure and thyroid cancer. Other risk factors include preexisting benign thyroid disease, irregular menstruation, bilateral oophorectomy, family history of thyroid malignancy, certain inherited syndromes, and residence in endemic goiter areas. Long-term alcohol and tobacco use do not appear to increase the risk of thyroid cancer.

Initial Evaluation

Thorough initial clinical evaluation of the patient with solitary thyroid nodule includes history of the thyroid mass, past medical history, family and social history, a careful review of systems, and a complete head and neck examination. Symptoms such as neck pain, stridor, dysphonia, and dysphagia increase clinical suspicion of a thyroid malignancy; however, none is diagnostic. Prior history of radiation exposure should be ascertained in all patients presenting with solitary thyroid nodule. Past medical history or family history of pheochromocytoma, hyperparathyroidism, chronic constipation and diarrhea, hypertension, and episodes of nervousness or excitability should alert the clinician of the possibility of familial MEN 2a or 2b syndrome.

Physical characteristics of a thyroid nodule are poor predictors of malignancy. Both malignant and benign solitary thyroid nodules can be soft or firm, smooth or irregular upon examination.

However, increased size of a thyroid nodule correlates with increased risk of malignancy. Moreover, size is used in tumor staging and is highly predictive of outcome. Fixation to or invasion of surrounding structures and the presence of palpable lymph nodes in the neck are also highly suggestive of malignancy. Vocal cord paralysis is not a reliable indicator of malignancy because it can also occur in benign disorders.

Thyroid function tests should be obtained as part of the initial evaluation of solitary thyroid nodule, and findings are usually normal in patients with thyroid cancer. Metabolic evidence of hyperthyroidism is more commonly associated with benign disorders such as an autonomously functioning adenoma or Hashimoto thyroiditis. A strong association exists between Hashimoto thyroiditis and primary thyroid lymphoma.

The measurement of serum thyroglobulin levels has historically not been recommended in the evaluation of solitary thyroid nodule because it is also elevated in benign thyroid disorders. There is more recent data to suggest that elevated serum thyroglobulin, thyroglobulin antibody, and Thyroid-Stimulating Hormone (**TSH**) levels may be associated with a higher risk of malignancy. Serum calcitonin and carcinoembryonic antigen (**CEA**) levels are usually elevated in patients with medullary thyroid carcinoma. However, serum CEA level has low specificity in the initial diagnosis of medullary thyroid carcinoma.

A retrospective study by Chami et al indicated that the measurement of serum TSH levels is not an effective means of screening for Autonomously Functioning Thyroid Nodules (**AFTNs**). The study involved 217 patients who had been diagnosed with an AFTN via thyroid scanning, in whom no thyroid nodules other than the AFTN were larger than 10 mm. The investigators found that TSH levels were normal in 49% of these patients and in 71% of the study's patients who underwent a scan during workup of the thyroid nodule [2].

DNA testing has proven to be an effective method for the diagnosis of MEN 2a and 2b syndromes. *ret* proto-oncogene in the paracentromeric region of the short arm of chromosome 10 is the site of mutation in 90% patients with familial medullary thyroid carcinoma and medullary thyroid carcinoma associated with MEN 2a and 2b. Patients with medullary thyroid carcinoma should undergo direct DNA analysis to identify possible germline mutations in the *ret* proto-oncogene. All family members should undergo similar testing if a *ret* mutation is identified. Family members with the *ret* mutation should undergo genetic counseling and be informed about prophylactic thyroidectomy.

Advances in molecular genetic testing hold the greatest promise for the development of a highly accurate serum marker to distinguish benign from malignant thyroid nodules. It is now possible to detect thyroid cancer cells in peripheral blood samples by measuring the mRNA of thyroid-specific genes, such as the mRNA of thyroglobulin and the thyrotropin receptor. In addition, microRNAs, which are small endogenous noncoding RNAs involved with the regulation of gene expression, can be detected in serum of patient's with thyroid cancer. Additional research

in this area may ultimately develop what is the holy grail of diagnostic tests for the evaluation of solitary thyroid nodules.

DIAGNOSTIC IMAGING

Ultrasonography

Ultrasonography is a safe and effective method of determining the size and the presence of solid or cystic components within a thyroid nodule. High-resolution ultrasonography can be used to determine the presence of nonpalpable nodules as small as 1 mm within the thyroid tissue. The predictive value of several ultrasonic features of thyroid nodules, including calcifications, margins, and vascularity, have been examined by numerous studies.

The addition of elastosonography in combination with high-resolution ultrasonography has significantly improved the diagnostic accuracy of ultrasound. The combination of these newer ultrasound techniques with molecular markers now available for fine-needle aspiration biopsy may prove to be able to distinguish malignant from benign thyroid nodules.

In a review of published studies, use of conventional thyroid ultrasonography did not allow accurate prediction of the histology of solitary thyroid nodules. In current practice, its main indications are the accurate measurement of size of the nodule, assessment for possible lymphadenopathy, and as a guide for Fine-Needle Aspiration Biopsy (**FNAB**) [3-6].

A study by Yuan et al, however, indicated that the patterns of enhancement differ significantly between benign and malignant solitary thyroid nodules examined with real-time, contrast-enhanced ultrasonography, with most malignant lesions in the report demonstrating an irregular shape, an unclear boundary, and inhomogeneous and incomplete enhancement. The study involved 78 patients, including 41 with benign lesions and 37 with malignant nodules [7].

Radionuclide Imaging

Radionuclide imaging has been the mainstay in the evaluation of solitary thyroid nodule since 1939 when Hamilton and Soley demonstrated that malignant thyroid tissue concentrates less radioactive iodine than normal thyroid tissue [8,9]. Thyroid nodules are further classified into cold, warm, and hot according to their ability to accumulate the radioactive isotope. Cold nodules are considered hypo functional, whereas warm nodules are normal and hot nodules are hyper functional. Iodine-123 and technetium (^{99m}Tc) are the most commonly used radio nuclides for thyroid imaging Figure 1.

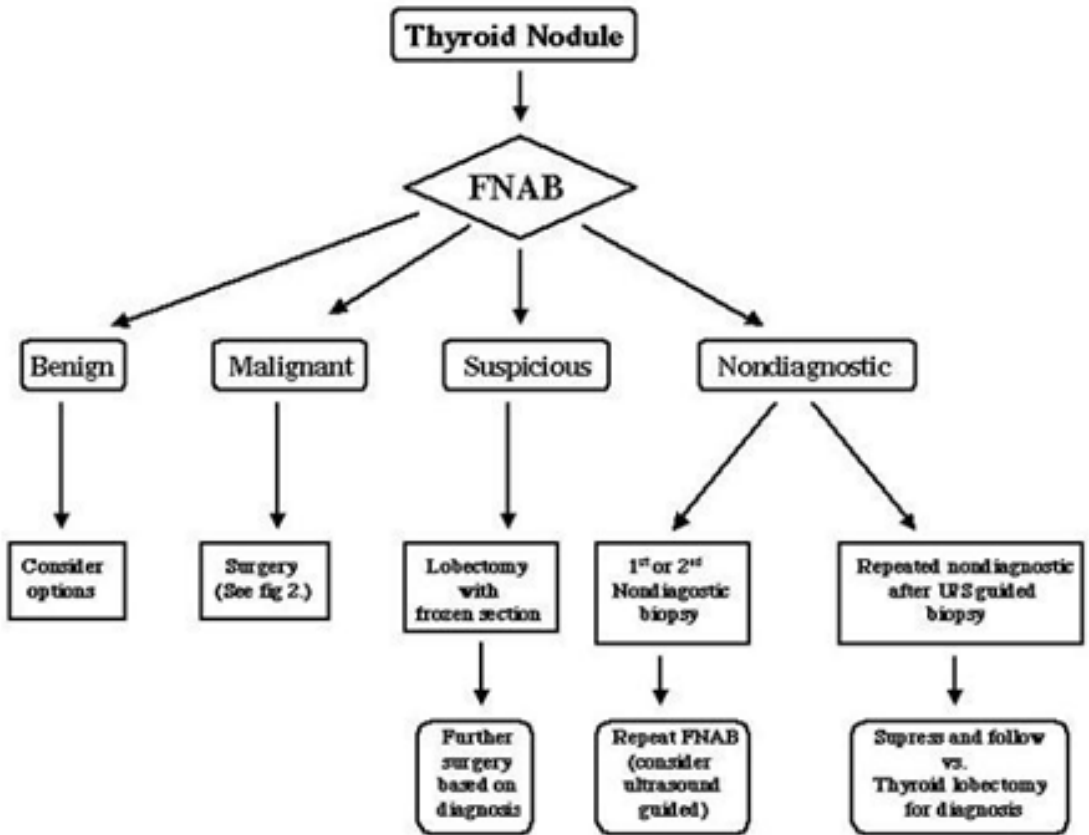


Figure 1: Algorithm for the management of a solitary thyroid nodule.

FNAB = Fine Needle Aspiration Biopsy; US = Ultrasonography.

The major limitation of thyroid radionuclide scanning has been its inability to distinguish between benign and malignant thyroid nodules with high accuracy. A review of published reports of radionuclide scanning reveals that 84% of solitary thyroid nodules are cold, 10% are warm, and the remaining 5% are hot. Malignant disease was found in 16% of cold nodules, 9% of warm nodules, and 4% of hot nodules. A cold thyroid nodule is more likely to be malignant, but most thyroid nodules are cold, including many benign lesions.

Other limitations of radionuclide scanning include an inability to delineate thyroid nodules at the periphery or isthmus of the thyroid gland and misinterpretation of the functional status of the thyroid nodule if normal functioning thyroid tissue overlies the cold solitary thyroid nodule or if the thyroid gland is asymmetric. Recent reports have shown some improvement in the diagnostic accuracy of ^{99m}Tc (MIBI) scanning when used in combination with FNAB. However, radionuclide scanning alone is not the most accurate technique to distinguish benign from malignant thyroid disorders.

Other Imaging Techniques

CT scanning and MRI have a limited role in the initial evaluation of solitary thyroid nodule [10]. Indications for these imaging techniques include suspected tracheal involvement, either by invasion or compression, extension into the mediastinum, or recurrent disease. Use of intravenous iodinated contrast agent in CT scanning makes thyroid scanning impossible because of the iodine load. The role of Positron Emission Tomography (**PET**) in the preoperative evaluation of follicular or indeterminate nodules remains unclear due to problems with accuracy. Routine use of PET scans in the evaluation of solitary thyroid nodules is not recommended at the present time.

Fine-Needle Aspiration Biopsy

Fine-Needle Aspiration Biopsy (**FNAB**) has become the diagnostic tool of choice for the initial evaluation of solitary thyroid nodule because of its accuracy, safety, and cost effectiveness. Fewer patients have undergone thyroidectomy for benign disease as a result of FNAB, with resultant decreased health care costs [11,12]. Although needle biopsy can be performed easily, consistently obtaining adequate tissue and processing the specimens to achieve accurate cytopathological interpretation requires expertise and experience. A satisfactory specimen should contain at least 5 or 6 groups of 10-15 well-preserved cells. Aspirated specimen is placed on glass slides and air-dried or fixed for staining. The adequacy of the specimen should be determined before the patient leaves.

FNAB specimens are classified as malignant, benign, indeterminate (suspicious for follicular or Hürthle cell neoplasm), or insufficient for diagnosis. In a comprehensive review of 28 series in which FNAB was performed on 10,872 patients with thyroid nodules, cytology was found to be benign in 53-90%, indeterminate or suspicious in 5-23%, malignant in 1-10%, and nondiagnostic in 2-21% of patients. Overall sensitivity, specificity, and accuracy of the FNAB technique have been reported to be 83%, 92%, and 95%, respectively. The effectiveness of FNAB of solitary thyroid nodules may be improved with the use of ultrasound guidance rather than simple palpation.

Accuracy of FNAB is closely related to the histologic type of thyroid carcinoma that is being evaluated. Papillary thyroid carcinoma is readily identified using FNAB because of its unique cytologic features. Diagnosis is correct for papillary thyroid carcinoma in approximately 90-100% of FNAB specimens when correlated with the histology of the final surgical specimen. Undifferentiated (anaplastic) carcinoma, medullary thyroid carcinoma, and primary thyroid lymphoma also have characteristic cytologic features, which aid correct diagnosis in approximately 90% of FNAB specimens.

The main limitation of FNAB is the differentiation of benign from malignant follicular neoplasms. FNAB specimens of follicular neoplasms and Hürthle cells are commonly interpreted as indeterminate or suspicious. This has resulted in low FNAB accuracy rates of approximately 40% for follicular carcinomas. Diagnosis of follicular carcinoma also requires the identification

of capsular and/or vascular invasion, which is not a possibility with FNAB techniques. Therefore, several techniques in addition to FNAB have been developed to increase the accuracy of FNAB for follicular carcinomas, including immune cyto chemistry techniques, large needle biopsy, and Intraoperative frozen section analysis.

Thyroid Peroxidase (**TPO**) immune cyto chemistry with a monoclonal antibody (MoAb 47) has been reported to significantly increase the accuracy of FNAB in patients with follicular lesions. Large-needle biopsy can also increase the diagnostic accuracy of FNAB, but it also increases the risk of hematoma, tracheal injury, laryngeal nerve injury or injury to other neck structures, and cutaneous implantation of malignant cells. Intraoperative frozen section analysis of thyroid nodules requires excisional biopsy in the form of thyroidectomy and may provide no additional information. Some authors report a high degree of accuracy with Intraoperative frozen section; however, its contribution to the management of solitary thyroid nodules remains controversial.

The application of molecular genetics to fine-needle aspiration biopsy holds great promise as an additional technique to help differentiate benign from malignant nodules and avoid surgery for benign thyroid disease. Several molecular markers, including BRAF, RAS, PAX8-PPAR γ , microRNAs, and loss of heterozygosity, have been studied as potential molecular tools for predicting malignancy in cytology specimens and may potentially help guide decisions regarding surgical management of nodular thyroid disease. The addition of cytologic molecular markers to nomograms of other clinically relevant information may also help the thyroid surgeon's ability to select those patients with solitary thyroid nodules at highest risk for malignancy [13-16].

EVALUATION AND MANAGEMENT STRATEGY

Following a comprehensive medical history and thorough physical examination, Fine-Needle Aspiration Biopsy (**FNAB**) should be considered the initial step in the evaluation of the solitary thyroid nodule. Depending on the interpretation of the FNAB cytologic specimen, management consists of observation, levothyroxine suppression therapy, or surgery.

Patients with benign solitary thyroid nodules may undergo observation or levothyroxine suppression therapy as the initial treatment modality. Levothyroxine is typically administered for 6-12 months to determine if the solitary thyroid nodule decreases in size. If the nodule decreases in size after treatment with levothyroxine, this medication is discontinued, with follow-up examination of the thyroid nodule in 3-6 months. However, if a benign solitary thyroid nodule increases in size, a repeat trial of levothyroxine and repeat FNAB may be indicated. Additionally, growth of a thyroid nodule during levothyroxine therapy is a strong indication for surgery [16-18].

No consensus exists regarding the degree of thyroid suppression or the efficacy of levothyroxine therapy. In fact, many endocrinologists no longer recommend thyroid suppression because of potential long-term adverse effects, such as osteoporosis and cardiac arrhythmias. Still others

maintain a Thyroid-Stimulating Hormone (**TSH**) level ranging from 0.1-0.3 mU/L rather than suppressing to the lowest limits of detectability to avoid immediate toxicity and long-term side effects.

Solitary thyroid nodules that are malignant, suspicious, or indeterminate on FNAB require excisional biopsy in the form of thyroidectomy. Considerable controversy exists regarding the extent of surgery for malignant, suspicious, or indeterminate solitary thyroid nodules [19-21].

References

1. Keh SM, El-Shunnar SK, Palmer T, Ahsan SF. Incidence of malignancy in solitary thyroid nodules. *J Laryngol Otol.* 2015; 129: 677-681.
2. Chami R, Moreno-Reyes R, Corvilain B. TSH measurement is not an appropriate screening test for autonomous functioning thyroid nodules: a retrospective study of 368 patients. *Eur J Endocrinol.* 2014; 170: 593-599.
3. Can AS, Peker K. Comparison of palpation-versus ultrasound-guided fine-needle aspiration biopsies in the evaluation of thyroid nodules. *BMC Res Notes.* 2008; 1: 12.
4. Goldfarb M, Gondek S, Solorzano C, Lew JI. Surgeon-performed ultrasound can predict benignity in thyroid nodules. *Surgery.* 2011; 150: 436-441.
5. Hegde A, Gopinathan A, Abu Bakar R, Ooi CC, Koh YY. A method in the madness in ultrasound evaluation of thyroid nodules. *Singapore Med J.* 2012; 53: 766-772.
6. Kihara M, Hirokawa M, Masuoka H, Yabuta T, Shindo H. Evaluation of cytologically benign solitary thyroid nodules by ultrasonography: a retrospective analysis of 1877 cases. *Auris Nasus Larynx.* 2013; 40: 308-311.
7. Yuan Z, Quan J, Yunxiao Z, Jian C, Zhu H. Contrast-enhanced ultrasound in the diagnosis of solitary thyroid nodules. *J Cancer Res Ther.* 2015; 11: 41-45.
8. Hamilton JG, Soley MH. Studies in iodine metabolism by use of a new radioactive isotope of iodine. *Am J Physiol.* 1939; 127: 557-572.
9. Choudhury M, Singh S, Agarwal S. Diagnostic utility of Ki67 and p53 immunostaining on solitary thyroid nodule--a cytohistological and radionuclide scintigraphic study. *Indian J Pathol Microbiol.* 2011; 54: 472-475.
10. Wu CW, Dionigi G, Lee KW, Hsiao PJ, Paul Shin MC, et al. Calcifications in thyroid nodules identified on preoperative computed tomography: Patterns and clinical significance. *Surgery.* 2012; 151: 464-470.
11. Basharat R, Bukhari MH, Saeed S, Hamid T. Comparison of fine needle aspiration cytology and thyroid scan in solitary thyroid nodule. *Patholog Res Int.* 2011; 2011: 754041.
12. Yip L, Farris C, Kabaker AS, Hodak SP, Nikiforova MN. Cost impact of molecular testing for indeterminate thyroid nodule fine-needle aspiration biopsies. *J Clin Endocrinol Metab.* 2012; 97: 1905-1912.
13. Ashcraft MW, Van Herle AJ. Management of thyroid nodules. I: History and physical examination, blood tests, X-ray tests, and ultrasonography. *Head Neck Surg.* 1981; 3: 216-230.
14. Barbosa GF, Milas M. Peripheral thyrotropin receptor mRNA as a novel marker for differentiated thyroid cancer diagnosis and surveillance. *Expert Rev Anticancer Ther.* 2008; 8: 1415-1424.
15. Blum M, Rothschild M. Improved nonoperative diagnosis of the solitary 'cold' thyroid nodule. Surgical selection based on risk factors and three months of suppression. *JAMA.* 1980; 243: 242-245.
16. Yu S, Liu Y, Wang J, Guo Z, Zhang Q. Circulating microRNA profiles as potential biomarkers for diagnosis of papillary thyroid carcinoma. *J Clin Endocrinol Metab.* 2012; 97: 2084-2092.
17. Fiore E, Vitti P. Serum TSH and risk of papillary thyroid cancer in nodular thyroid disease. *J Clin Endocrinol Metab.* 2012; 97: 1134-1145.
18. Gharib H. Fine-needle aspiration biopsy of thyroid nodules: advantages, limitations, and effect. *Mayo Clin Proc.* 1994; 69: 44-49.
19. Gibb GK, Pasieka JL. Assessing the need for frozen sections: still a valuable tool in thyroid surgery. *Surgery.* 1995; 118: 1005-1009.
20. Grebe SKG, Hay ID. Clinical evaluation of thyroid tumors. Thawley SE, Panje WR, Batsakis, editors. *Comprehensive Management of Head and Neck Tumors.* Philadelphia, Pa: WB Saunders Co. 1999; 1694-1709.
21. Haff RC, Schecter BC, Armstrong RG, Evans WE. Factors increasing the probability of malignancy in thyroid nodules. *Am J Surg.* 1976; 131: 707-709.