

Emerging Aspects of Neoadjuvant Immunotherapy in High Risk Melanoma

E George Elias^{1*} and Bhuvnesh K Sharma²

¹University of Maryland St. Joseph Medical Center, USA

²SckTek Laboratories, Logan, Utah, USA

***Corresponding author:** E George Elias, University of Maryland St. Joseph Medical Center, USA, Tel: 410-296 1344; Fax: 410-296 1344; Email: egelas1@comcast.net

Published Date: June 30, 2016

ABSTRACT

Background: Cutaneous melanoma is an immunogenic tumor, but it seems to be very heterogeneous.

Methods: Utilizing patient own tumor as the source for tumor-specific antigens, intralesional administration of GM-CSF as 500 μg once/week could activate dendritic cells at the tumor site. Failure to establish Complete Response (**CR**), IL-2 was substituted at 11 million IU weekly to activate T lymphocytes. This autologous approach seemed to overcome tumor heterogeneity.

Results: Three of four patients with in-transit metastases, including one with un-resected primary lesion, had CR to GM-CSF. One failed but had CR to intralesional IL-2. Two patients with distant metastases with palpable subcutaneous nodes had CR at the injection sites only; one to GM-CSF and the other to IL-2. The sites of CR were biopsied 6-8 weeks after cessation of therapy revealed no residual tumor or mononuclear cell infiltrates. Patient with an invasive primary cutaneous melanoma with a satellite metastasis received GM-CSF followed by IL-2 on two consecutive days at the primary and the satellite, one week prior to surgical resection. The resected tissue showed complete tumor necrosis with massive histiocytosis at both injection sites. There was also an over expression of cytotoxic T cells (CD8+), helper cells (CD4+), and mature DCs (CD83+) at the injection sites and in some regional lymph nodes. The overall duration of response ranged from 31-60 months to date.

Conclusion: *In vivo* autoimmunization of melanoma sites by intralesional administration of the cytokines seemed to induce an immense antitumor response that was transmitted via the lymphatics and seemed to prolong patient survival.

Keywords: Preoperative; Intralesional; Cytokine; Therapy; Survival; Benefits

Abbreviations: (GM-CSF): Granulocyte-Macrophage Colony Stimulating Factor (also known as Leukine) manufactured by Sanofi-Aventis Corporation; Bridge Water, New Jersey, USA.

(IL-2): Interleukin-2 (also called Aldesleukin) manufactured by Chiron Corporation; Emeryville, California, USA.

INTRODUCTION

Cutaneous melanoma is an immunogenic tumor as it expresses various melanoma-specific antigens. However, it seems to be very heterogeneous as it expresses different melanoma antigens and has diverse genetic profiles among different patients. To overcome such heterogeneity, tumor-specific and autogenic therapeutic approach could be essential to obtain an antitumor immune response. It has been shown that patients with resected metastatic melanoma who have melanoma-specific Infiltrating Lymphocytes (**TILs**) in the resected metastases have statistically better survival than those who have melanoma-specific T cells in the peripheral blood [1]. Furthermore, the higher the number of TILs at the primary sites of melanoma carries better prognosis [2]. Therefore, the activation of these cells at the tumor site is a logic approach to obtain antitumor immune response.

Patients' own tumors could be utilized as the source for melanoma-specific antigens, and activating the local immune response at the tumor site could overcome such heterogeneity. In the meantime, two cytokines have shown activity in the management of dermal metastatic melanoma. These included Granulocyte-Macrophage Colony Stimulating Factor (**GM-CSF**) and Intrleukin-2 (**IL-2**).

GM-CSF is a multifunctional molecule administered as a single agent in dermal metastases can increase the number and activation of autologous Dendritic Cells (**DCs**), T cell infiltrate at the tumor site particularly helper cells and increase the expression of IL-2 receptors (IL-2R) on some T lymphocytes. DCs are very efficient Antigen Presenting Cells (**APCs**) capable of processing tumor antigens and present the processed antigens by crosstalk to T lymphocytes in the context of major histocompatibility class I and II molecules. DCs are also rich in co-stimulatory factors such as B7-1 and B7-2 which are needed to complete the second immune signal to T lymphocytes which become committed to specific immune response. Its intralesional administration at doses of 10-80 μg has shown its biological effects but without major clinical response [3,4]. However, when the doses were increased to 400-500 μg daily for 4-5 consecutive days and repeated every 21-28 days, it has given excellent clinical responses but with some side effects [5,6]. On the other hand, IL-2 is a glycoprotein immune modulator [7]. Its intralesional administration as a single agent in in-transit metastatic melanoma at doses ranging from 0.6-6.0 million IU, 2-3 times per week or with escalating doses has resulted in Complete Tumor Response (**CR**) in two thirds of the patients, but with grade I and II toxicity especially at the higher doses [8-10].

To investigate the effect of sequential administration of intralesional GM-CSF and IL-2 in melanoma lesions, dermal and subdermal lesions were chosen as these lesions were accessible for intralesional therapy and could be repeatedly inspected, palpated and easily biopsied to confirm the effect of therapy. Low doses of both cytokines were utilized to avoid toxicity. GM-CSF was administered first, and in case of failure to obtain CR, intralesional IL-2 was substituted.

MATERIAL AND METHODS

This exploratory study was approved by the Institution Review Board, with the main objective was to evaluate the local effects of weekly intralesional administration of low-dose of GM-CSF and IL-2 in patients with dermal and subdermal melanoma lesions. A secondary objective was to observe for any systemic benefits or side effects. Patients with dermal and subdermal metastases were studied, regardless to the extent of the disease, anatomic site of involvement or previous therapy. The study patient did not receive any other anticancer therapy while on the study. None of the lesions were evaluated for their tumor antigenicity or genetic expressions. However, the treated tumor sites had pathological confirmation of the presence of melanoma.

Prior to initiating the therapy, each patient underwent complete work-up that included complete history and physical examination, complete peripheral blood cell counts with differential (**CBC**), serum electrolytes with hepatic and renal function tests and Lactic Dehydrogenase (**LDH**). Positron Emission Tomography with Computed Tomography (**PET/CT**) was performed to identify the extent of the disease. The study was explained to the patient and after signing the consent form, the dermal lesions were photographed and the palpable subcutaneous lesions had their site marked on the skin with non-washable marker and photographed.

During either cytokine therapy, the injection did completely fill each lesion or group of lesions with the cytokine. Each patient was evaluated weekly by complete physical examination with all the blood tests repeated every two weeks. When complete clinical response was achieved, intralesional therapy was discontinued and the patient was placed under close observation with clinical evaluation and laboratory tests performed every two weeks for two months, then every three months for the first two years. PET/CT scans were repeated every 6 months unless otherwise indicated. On the other hand, patients with distant metastases had their scans repeated every two months.

Complete tumor response was characterized by complete disappearance of the tumor clinically at the injection sites confirmed pathologically by repeated biopsy of the treated site 6-8 weeks after cessation of therapy.

Ten patients consented to the study, shown in table 1.

Table 1: Demographics of the study patients & summary of the results.

Patient No.	Age	Sex	Type of lesion	Site treated & location	Prior therapy	Cytokine used	Response to cytokine	Disease Free period (months)	Overall Response period (months)
1	39	F	I-M	Skin, SC Thigh	Multiple excisions	GM-CSF	CR	22	48
2	69	M	Primary + I-M	Scalp	BCG	GM-CSF	CR	60	60
3	52	F	I-M	SC Thigh & leg	Excisions HILP, LI, BCG	GM-CSF IL-2	None CR	- 12	- 36
4	44	M	I-M	SC Thigh	Excision, HILPx2, RT	GM-CSF	CR	12	31
5 (X)	63	F	D M	SC neck	Systemic	GM-CSF	CR	< 6 Systemic failure	N/A
6 (X)	50	F	D M	SC Axilla	systemic	GM-CSF IL-2	None CR (locally)	Systemic failure	N/A
7	74	M	Local recur	Skin, SC shoulder	Excision BCG	GM-CSF IL-2	None None	N/A N/A	N/A N/A
8	67	M	Local recur	scalp	Excision RT	GM-CSF IL-2	None None	N/A N/A	N/A N/A
9	51	M	Local recur	Skin, SC Neck	Excisions BCG	GM-CSF IL-2	None None	N/A N/A	N/A N/A
10	70	M	Primary + satellite	Forearm	None	GM-CSF + IL-2	CR	60	60

I-M= In-Transit Metastases;

LI= Limb Infusion

DM= Distant Metastases

SC= Subcutaneous Tissue Recur= Recurrence

HILP= Hyperthermic Limb Perfusion;

LI= Limb Infusion

RT= Radiation Therapy

(X) Both patients had CR locally at the injection site, but failed systemically and received other therapy.

Their ages ranged from 39-74 years. There were six men and four women. Six of them (#1-6) had multiple small lesions, each measured one cm or less, with patient #2 presenting with massive in-transit metastases to the scalp, and the primary had not been previously identified or excised, as it was difficult to identify because of the massive in-transit metastases, Figure 1.

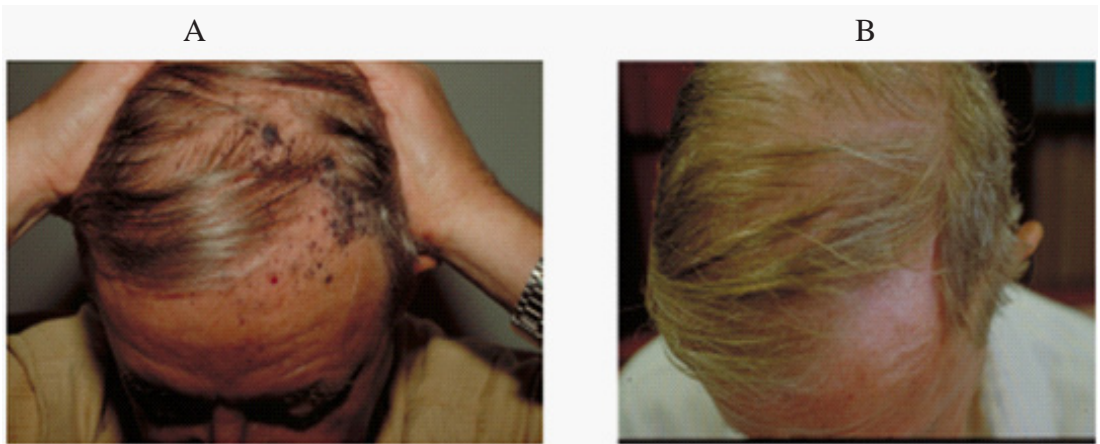

Figure 1: Shows the clinical response in patient #2.

- A. Photograph of the scalp before intralesional therapy. The patient presented with multiple in-transit metastases with unidentified primary site among the metastases.
- B. Photograph after intralesional therapy with GM-CSF. Notice the complete response in the form of disappearance of all lesions. The patient received no other treatment and had no recurrence or metastases for over 5 years.

Two patients (#5 and 6) had subdermal metastases as part of systemic disease. Three patients (#7-9) had large sclerotic coalesced skin lesions of over 3 cm each but without evidence of regional or systemic metastases. All the nine patients were previously treated for their metastases by various methods including repeated local excisions, intratumoral BCG, hyperthermic isolated limb perfusion with melphalan, limb infusion, radiation therapy, systemic chemotherapy and combinations of the above, table 1. Two patients (#1,3) were also failure to previous adjuvant therapy with higher doses of GM-CSF and IL-2 that included postoperative subcutaneous administration of GM-CSF: 125 $\mu\text{g}/\text{m}^2/\text{day}$ for 14 consecutive days followed by IL-2: 9 million IU/ m^2/day for 4 days, repeated every month for 2 years. They developed in-transit metastases; one within a year of initiating adjuvant therapy, and the other 3 months after completing 2 years of the adjuvant therapy. Two patients (#5,6) had palpable subdermal metastatic lymph nodes with distant metastases: one had bilateral palpable supraclavicular metastatic lymph nodes and metastasis to the left iliac lymph node, and the other had palpable metastatic lymph node under the skin of the right anterior axillary fold with metastases to both lungs.

Initially, each of the nine patients (#1-9) received GM-CSF: 500 microgram (μg) administered once per week to as many lesions per setting, but not to exceed the weekly dose. In case of any toxicity, allergic reaction or failure to establish CR in four weeks at the injection sites, GM-CSF therapy was discontinued and substituted by intralesional IL-2 at 11 million IU weekly for the same length of time. Patients whose tumor failed to show complete response at the injection sites to both cytokines were taken off the study and treated with other therapeutic modalities. Patients with distant metastases whose distant tumors failed to show any response were also taken of the study as they were placed on systemic therapy.

In addition, patient (#10), presented with an invasive primary cutaneous melanoma of 1.9 mm depth of invasion with a satellite metastasis and one enlarged regional lymph node (presumably metastatic), who was not previously treated and remained to be a surgical candidate but with very guarded prognosis. This patient received intralesional therapy with GM-CSF: 500 μg at the primary and satellite sites on day 1, followed by IL-2: 11 million IU at both sites on day 2, just one week before the planned surgical resection.

RESULTS

There was no clinical evidence of any side effects in any of the treated patients except for mild to moderate skin reaction at the injection sites. No significant changes were noted in the CBC or serum chemistries including LDH. None of the patients without distant metastases developed systemic dissemination.

Three of four patients with in-transit metastases had CR to GM-CSF, including patient #2 who had a primary lesion and in-transit metastases, Figure 1. One patient (#3) failed GM-CSF therapy but had CR to IL-2. Two patients (#1, 3) who were previously treated by systemic adjuvant therapy with relatively higher doses of both cytokines and developed in-transit metastases, had CR to intralesional therapy; one to GM-CSF and the other to IL-2. The histopathological examination of some of the treated sites that had CR to either cytokine were re-biopsied 6-8 weeks after cessation of the therapy revealed no residual tumor cells or mononuclear cell infiltrates. However, three patients (#1,3) who had previously received both cytokines, and patient #4 who was previously treated by hyperthermic isolated limb perfusion and radiation therapy, each developed a single new in-transit metastasis, in none of the treated sites by intralesional therapy, at 12 to 22 months after cessation of therapy and were managed by local excision only and had an additional 19 to 26 month disease-free survival, table 1.

Furthermore, each of the in-transit lesions that were less than 1 cm in size had complete response after one or two injections of the cytokine. In addition, in a given patient, when one lesion responded to intralesional therapy with either cytokine, all other lesions did also respond to the same therapy. The overall duration of response ranged from 31-60 months, table 1.

One of the two patients with systemic metastases had CR to GM-CSF at the injection sites and at the distant metastatic iliac lymph node for six months but in the meantime developed bilateral adrenal metastases. The other patient had no response to GM-CSF at the injection site but had CR to IL-2 without any response or progression of the lung metastases.

The three patients with recurrent large sclerotic skin lesions failed to respond to either cytokine therapy.

The histopathological examination of the resected tissues of patient #10 who received GM-CSF followed by IL-2 on two consecutive days, one week prior to the surgical resection, revealed complete tumor necrosis with massive histiocytosis at the injection sites, Figure 2.

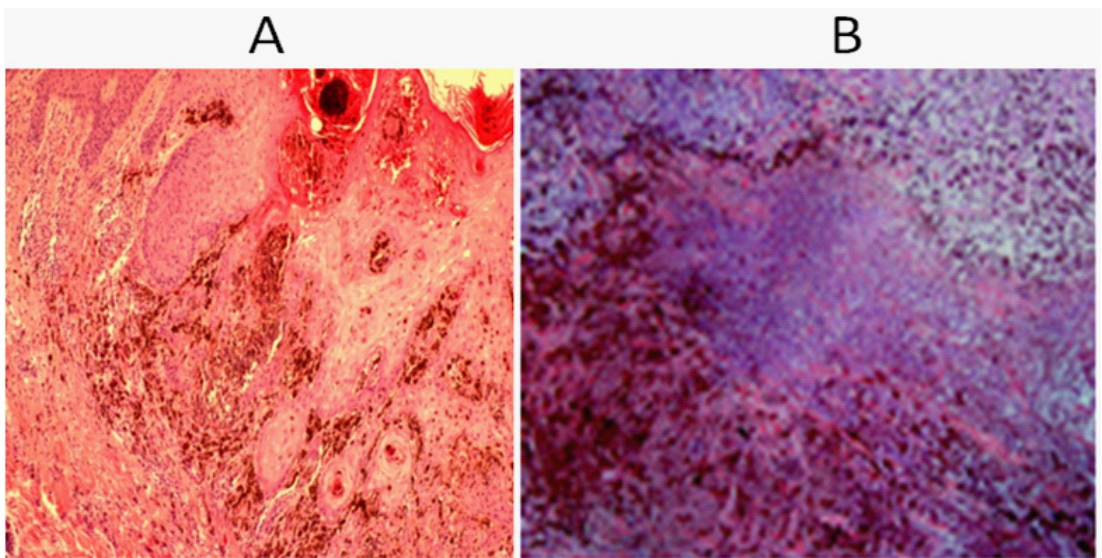


Figure 2: The histopathological response in patient #10.

- A. Before intralesional therapy from the biopsy site. Notice the depth of invasion.
- B. One week after intralesional therapy with GM-CSF followed by IL-2 administered on 2 consecutive days. Notice the complete tumor necrosis with the massive histiocytosis. X 400, H & E stain.

However, the enlarged regional lymph node, that measured 3 cm in size, contained metastases. Immunohistochemistry studies of the resected tissues showed over expression of CD3+ for total T cell, CD8+ cytotoxic T cells, CD4+ helper cells and CD83+ for mature dendritic cells [11] at the primary site, Figure 3, the satellite and in some regional lymph nodes that contained no metastases, Figure 4. This patient is alive free of disease for over 5 years.

DISCUSSION

Intralesional therapy with low dose GM-CSF and IL-2 was safe, well tolerated and seemed to be more effective than the more frequent intralesional administration of higher doses of either cytokine. In addition, none of the treated patients had any systemic side effects in the form of fever, chills, fatigue, rash or any significant changes in their CBC or serum chemistry including the LDH.

Early trials with adjuvant therapy, administered after resection of the melanoma, included non-specific immune stimulants such as Bacillus Calmette Guerin (**BCG**), *Corynebacterium parvum*, levamisole or combinations of these agents with and without chemotherapy with decarbazine (**DTIC**) revealed no significant impact on the disease [12]. In addition, adjuvant vaccines trials were ineffective and sometimes harmful except with autologous melanoma vaccine [13]. High dose interferon α -2b for one year initially showed significant improvement in disease-free and overall survival [14]. However, the overall survival benefit was not sustained overtime [15].

This approach was nontoxic and relatively cheaper than any futuristic adjuvant therapeutic approach such as the use of anti-Cytotoxic T Lymphocyte Associated Antigen-4 (anti **CTLA-4**) or anti-Program Cell Death and its Primary Legend (anti PD-1 and PDL-1) which showed some survival benefits in patients with metastatic melanoma [16,17]. A recent adjuvant study by the European group proved this point utilizing anti CTLA-4 (Ipilimumab) after surgical resection of stage III melanoma showed some early success but with 48% recurrence rate at a median of 2.7 years, with grade 3 and 4 immune related adverse events and the therapy was discontinued in 52% of the treated patients [18].

In the present study, failure to obtain complete tumor response with intralesional GM-CSF was successfully rescued by IL-2 therapy. Therefore, it seemed that some melanoma lesions did respond to the activation of dendritic cells by intralesional GM-CSF, while other lesions required the activation of the cytotoxic T cells by IL-2. Therefore, the sequential administration of both cytokines seemed to be justified.

Intralesional therapy with these cytokines utilized the tumor site as the source for tumor-specific antigens of each patient. It was effective in metastatic lesions as well as in primary invasive melanoma. Seven of the ten patients had complete tumor response to cytokine therapy at the injection sites. The other three patients with large sclerotic skin lesions failed to show any response probably due to the large tumor load and the sclerotic nature of the lesions due to previous therapy that could not be handled immunologically. Hypothetically, such lesions could be excised followed by cytokines injections at the margins of the resection for two weeks prior to skin grafting.

It was of interest to notice the absence of any residual tumor cells or mononuclear cell infiltrates 6-8 weeks after complete clinical response to intralesional cytokine therapy. This could

indicate an immense antitumor response to the therapy with complete washout of the local effects over such period of time. This was further confirmed by evaluating the resected tissue one week after preoperative intralesional administration of both GM-CSF and IL-2, which clearly showed an efficient immune response within days after the administration of intralesional therapy with both cytokines at the injection sites, Figure 3.

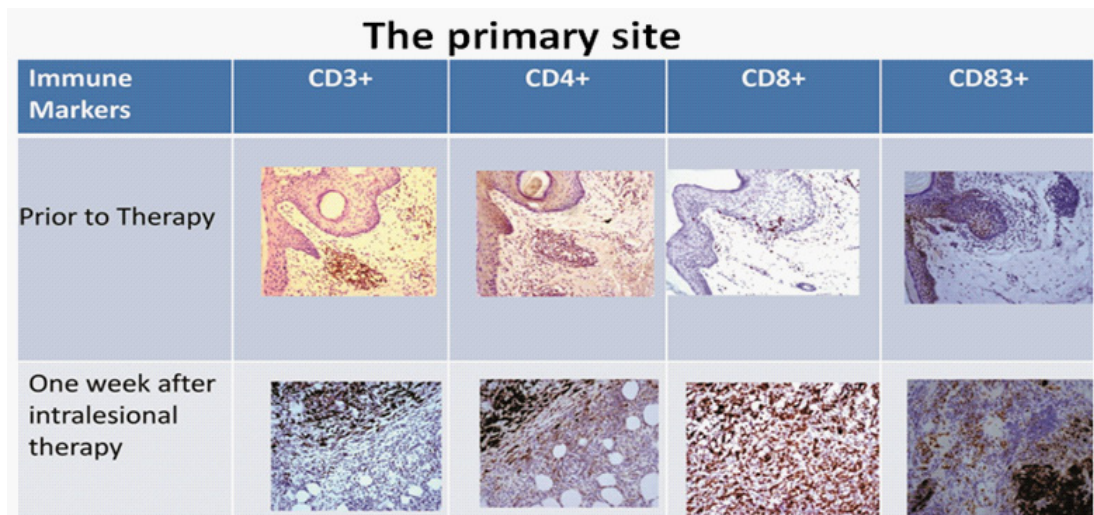


Figure 3: Immunohistochemistry response at the primary site of melanoma in patient #10.

Note the over expression of the immune cells (CD3+, CD4+, CD8+ and CD83+ cells), One week after Intralesional administration of GM-CSF and IL-2 compared to before therapy from the biopsy site of the same lesion. Dark cells express the immune cells. X 400 using commercially available antibodies.

Furthermore, the presence of the cytotoxic T cells, helper cells and mature dendritic cells in these lymph nodes that contained no metastases, Figure 4, might suggest that such an immune response was taken-up by the lymphatic system and could have possibly been eliminated early micro-metastases in a patient with stage IIIC disease. Such findings confirm other reports that the administration of GM-CSF near the biopsy site of primary cutaneous melanoma can increase the number and activation of dendritic cells and tumor-specific cytotoxic T cells in sentinel lymph node [19,20].

The Regional Lymph Node

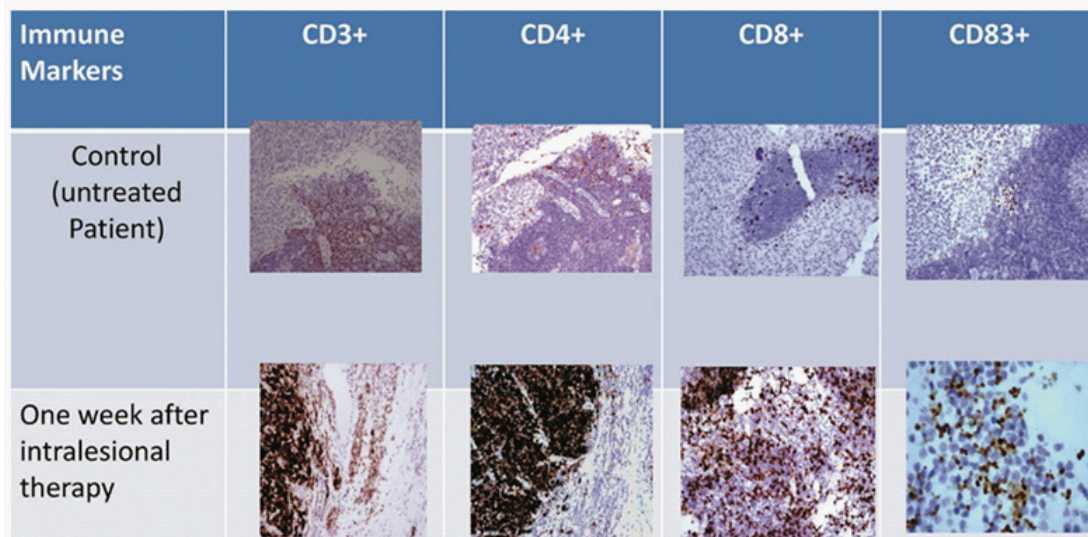


Figure 4: Immunohistochemistry response in the regional lymph node of a patient who did not receive preoperative intralesional therapy compared to patient #10 who received GM-CSF and IL-2 just one week before. Notice the over expression of all immune cells. X 400 using commercially available antibodies.

The route of the administration of a vaccine can be a critical variable in determining the outcome of an immune response. In an animal model, when a vaccine with naked antigen-encoding RNA is being administered in the skin, subcutaneous tissue or near a lymph node, no significant immune response has been noted. However, when this vaccine is administered in a lymph node, it elicited potent prophylactic and therapeutic antitumor immunity [21]. Therefore, it was no surprise to obtain CR in two patients who failed systemic adjuvant therapy with both cytokines but responded to intralesional therapy with low doses of the same cytokines.

Furthermore, the two patients with distant metastases (#5,6) had CR at the injection sites, with patient # 5 had CR in the distant metastatic iliac lymph node after intra-lymphatic cytokine therapy at the supraclavicular lymph nodes. This could suggest a questionable role for intra-lymphatic injection of these cytokines. However, while intralesional therapy could initiate an antitumor immune response in patients with distant metastases, it would need systemic support as the injected sites (source of antigen) did dissolve after the initial intralesional therapy, and therefore such therapy could not be continued. We could speculate that patients with limited distant metastases could be treated with intralesional cytokine therapy utilizing sonographic or CT control.

The recurrences at 12 and 22 months in patients #1,3 could be due to the development of some tolerance from previous systemic adjuvant therapy with both cytokines. On the other hand, patient #4 who developed a recurrence in 12 months after intralesional therapy, was previously treated with hyperthermic isolated limb perfusion with melphalan and radiation therapy, might have been partly immune compromised compared to patient #2 who was previously treated by intralesional biological agent such as BCG, and had no recurrence after intralesional GM-CSF therapy for over 60 months. Such recurrences could have been managed by repeated intralesional cytokine therapy at the recurrence sites rather than by surgical excisions.

The durable response in primary melanoma lesions (patients #2 and 10) could suggest a role for preoperative intralesional administration of both cytokines as a neoadjuvant therapy in high risk primary melanoma, and newer prospects of targeted cancer therapy. Furthermore, this study showed a promising anticancer therapeutic strategy which could be reliant on formation of an immune microenvironment at the tumor site.

This specific autologous approach had its limitation as it should not be used in infected lesions or with allogenic antigens as it may result in an immune deviation. An example can be seen in two reports of active immunization with two vaccines; one with multi-peptides and the other with allogenic whole melanoma cells +3 peptides in combination with GM-CSF that resulted in a negative outcome [22,23]. The authors blamed such negative results on the use of GM-CSF, but the fact is that their antigens use of peptides or allogenic cells did not express patients' own tumor antigens and the induced immune response by GM-CSF was directed to the administered antigens.

Furthermore, the response seen with intralesional therapy with these two cytokines targeted the whole tumor cells that could be regardless to its antigenic or genetic profiles. It can also replace the repeated surgical excision of local recurrences and in-transit metastases.

CONCLUSION

In conclusion, intralesional administration of GM-CSF and IL-2 prior to the surgical resection as a neoadjuvant immunotherapy is non-toxic and effective in the management of patients with in-transit metastases and satellitosis as well as in patients who present with high risk primary melanoma. These new findings warrant the initiation of prospective controlled randomized studies.

References

1. Haanen JB, Baars A, Gomez R, Weder P, Smits M, et al. Melanoma-specific tumor-infiltrating lymphocytes but not circulating melanoma-specific T cells may predict survival in resected advanced-stage melanoma patients. *Cancer Immunol Immunother.* 2006; 55: 451-458.
2. Azimi F, Scolyer RA, Rumcheva P, Moncrieff M, Murali R, et al. Tumor-infiltrating lymphocyte grade is an independent predictor of sentinel lymph node status and survival in patients with cutaneous melanoma. *J Clin Oncol.* 2012; 30: 2678-2683.
3. Si Z, Hersey P, Coats AS. Clinical responses and lymphoid infiltrates in metastatic melanoma following treatment with intralesional GM-CSF. *Melanoma Res.* 1996; 6: 247-255.
4. Nasi ML, Lieberman P, Busam KJ, Prieto V, Panageas KS, et al. Intradermal injection of granulocyte-macrophage colony-stimulating factor (GM-CSF) in patients with metastatic melanoma recruits dendritic cells. *Cytokines Cell Mol Ther.* 1999; 5: 139-144.

5. Vaquerano JE, Cadbury P, Tressler P, Sagebiel R, Leong SPL. Regression of in-transit melanoma of the scalp with intralesional recombinant human granulocyte-macrophage colony-stimulating factor. *Arch Dermatol.* 1999; 135: 1276-1277.
6. Hoeller C, Jansen B, Heere-Ress E, Pustelnik T, Nossbacher U, et al. Perilesional injection of r-GM-CSF in patients with cutaneous melanoma metastases. *J Invest Dermatol.* 2011; 17: 371-374.
7. Medzhitov R, Janeway C. Innate immune recognition: mechanisms and pathways. *Immunol Rev.* 2000; 173: 89-97.
8. Radny P, Caroli UM, Bauer J, Paul T, Schlegel C, et al. Phase II trial of intralesional therapy with interleukin-2 in soft-tissue melanoma metastases. *Br J Cancer.* 2003; 89: 1620-1626.
9. Dehesa LA, Vilar-Alejo J, Valerón-Almazán P, Carretero G. [Experience in the treatment of cutaneous in-transit melanoma metastases and satellitosis with intralesional interleukin-2]. *Actas Dermosifiliogr.* 2009; 100: 571-585.
10. Weide B, Derhovanessian E, Pflugfelder A, Eigentler TK, Radny P, et al. High response rate after intratumoral treatment with interleukin-2: results from a phase 2 study in 51 patients with metastasized melanoma. *Cancer.* 2010; 116: 4139-4146.
11. Cao W, Lee SH, Lu J. CD 83 is performed inside monocytes, macrophages and dendritic cells, but it is only stably expressed on activated dendritic cells. *Biochem J.* 2005; 385: 85-93.
12. Eggermont AM, Gore M. Randomized adjuvant therapy trials in melanoma: surgical and systemic. *Semin Oncol.* 2007; 34: 509-515.
13. Berd D, Maguire HC, Schuchter LM, Hamilton R, Hauck WW, et al. Autologous hapten-modified melanoma vaccine as postsurgical adjuvant treatment after resection of nodal metastases. *J Clin Oncol.* 1997; 15: 2359-2370.
14. Kirkwood JM, Strawderman MH, Ernstoff MS, Smith TJ, Borden EC, et al. Interferon alfa-2b adjuvant therapy of high-risk resected cutaneous melanoma: the Eastern Cooperative Oncology Group Trial EST 1684. *J Clin Oncol.* 1996; 14: 7-17.
15. Kirkwood JM, Ibrahim JG, Sondak VK, Richards J, Flaherty LE, et al. High- and low-dose interferon alfa-2b in high-risk melanoma: first analysis of intergroup trial E1690/S9111/C9190. *J Clin Oncol.* 2000; 18: 2444-2458.
16. Haanen JB. Immunotherapy of melanoma. *EJC Suppl.* 2013; 11: 97-105.
17. Eggermont AM. Adjuvant therapy for high-risk melanoma. *EJC Suppl.* 2013; 11: 106-108.
18. Eggermont AM, Chiarion-Sileni V, Grob JJ, Dummer R, Wolchok JDS, et al. Adjuvant ipilimumab versus placebo after complete resection of high-risk stage III melanoma (EORTC18071): a randomized, double-blinded phase 3 trial. *Lancet Oncol.* 2015; 16: 522-530.
19. Vuylsteke RJ, Molenkamp BG, Gietema HA, van Leeuwen PA, Wijnands PG, et al. Local administration of granulocyte/macrophage colony-stimulating factor increases the number and activation state of dendritic cells in the sentinel lymph node of early-stage melanoma. *Cancer Res.* 2004; 64: 8456-8460.
20. Vuylsteke RJ, Molenkamp BG, van Leeuwen PAM, Meijer S, Wijnands PGJT, et al. Tumor-specific CD8+ T cell reactivity in sentinel lymph node of GM-CSF-treated stage I melanoma patients is associated with high myeloid dendritic cell content. *Clin Cancer Res.* 2006; 12: 2826-2833.
21. Kreiter S, Selmi A, Diken M, Koslowski M, Britten CM, et al. Intranodal vaccination with naked antigen-encoding RNA elicits potent prophylactic and therapeutic antitumoral immunity. *Cancer Res.* 2010; 70: 9031-9040.
22. Slingluff CL, Petroni GR, Olson WC, Smolkin ME, Ross MI, et al. Effect Of granulocyte/macrophage colony-stimulating factor on circulating CD8+ and CD4+ T-cell response to a multipptide melanoma vaccine: outcome of a multicenter randomized trial. *Clin Cancer Res.* 2009; 15: 7036-7044.
23. Faries MB, Hsueh EC, XY, Hoban M, Morton DL. Effect of granulocyte/macrophage colony-stimulating factor on vaccination with an allogenic whole-cell melanoma vaccine. *Clin Cancer Res.* 2009; 15: 7029-7035.