

# Surgical Approach to Renal Transplantation

**Dietric L Hennings<sup>1</sup> and Anil S Paramesh<sup>1</sup>**

<sup>1</sup>Department of Surgery, Tulane University School of Medicine, USA

**\*Corresponding author:** Anil S Paramesh, Tulane Abdominal Transplant Institute, Tulane University School of Medicine, New Orleans, Louisiana, USA, Tel: 504-988-0783; Email: [aparames@tulane.edu](mailto:aparames@tulane.edu)

**Published Date:** January 30, 2016

## INTRODUCTION

The first kidney transplantation took place in 1954 by Murray between monozygotic twins [1]. Murray received a Nobel Prize for his contributions and began the modern era of transplantation. The process of kidney transplantation requires many well organized and calculated steps starting with organ donation, either living or deceased. The kidney is then prepared for implantation into the recipient. Post-operative follow-up is essential in transplant patients for close monitoring, medication management, and treatment of any possible complications. Below we discuss the transplantation surgical process in detail, outlining the definitive treatment for End Stage Renal Disease: improving survival, improving quality of life and reducing the burden on the medical system [2-4].

# KIDNEY DONATION

While there is a push to increase living donation, deceased donation remains the major source of donated kidneys

## DECEASED DONATION

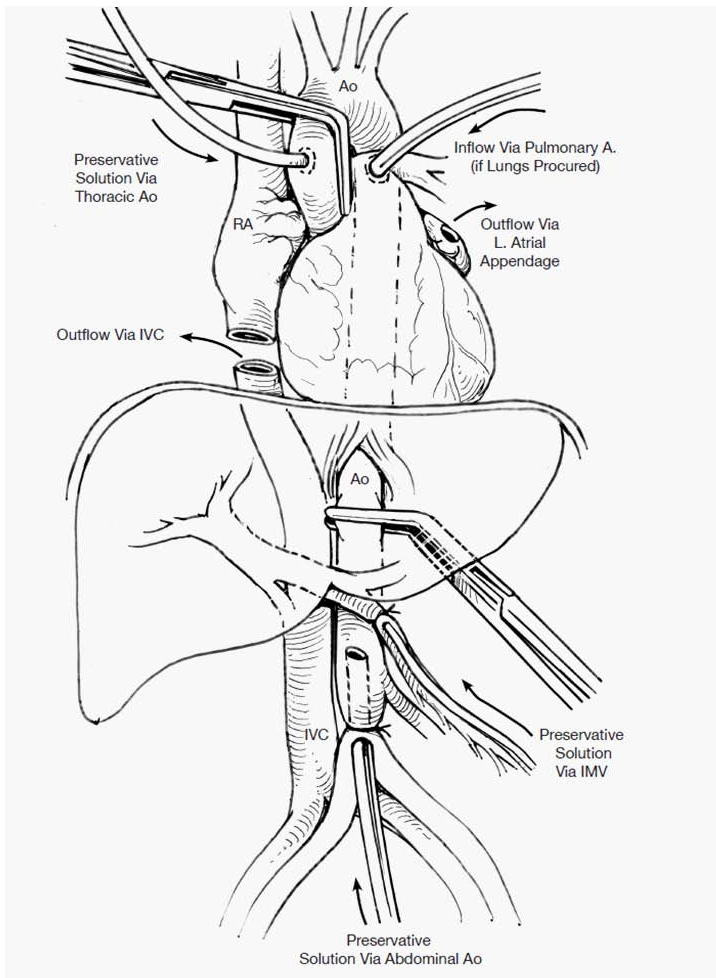
Deceased donors are evaluated for organ donation by local Organ Procurement Organizations (OPOs), under the governance of the United Network of Organ Sharing. During this process, organ donors are evaluated for medical comorbidities, infectious risks and suitability of organs.

If the kidneys are to be removed alone, bilateral nephrectomy is carried out through a midline incision from the sternum to the pubis. En bloc resection of the kidneys, along with the aorta and vena cava is undertaken to avoid disruption of accessory vessels, present in 12-15% of the population, which can later be dealt with during the backtable preparation. Furthermore, this technique limits warm ischemia time. Continuous perfusion of preservative solution (UW Solution, Euro-Collins Solution etc.) is carried out through direct cannulation of the aorta. This technique avoids direct cannulation of the renal vasculature, which decreases warm ischemic time as well as the potential for intimal injury of the renal vasculature inherent to cannulation [4].

Upon making the midline incision and entering the donor abdomen, rapid exploration is undertaken to ensure absence of disease such as infection, neoplasm, or other systemic diseases contraindicating donation. The small bowel is retracted to the right of the donor and the parietal peritoneum lining the posterior abdomen is incised, exposing the great vessels. The peritoneal incision is extended around the white line of Toldt to free the right and left colon from their peritoneal attachments and allow for superior retraction of the entire bowel. The duodenum and pancreas are also retracted superiorly. The proximal aorta is circumferentially freed and isolated above the celiac axis and the superior mesenteric artery.

Umbilical tape or large silk suture is then passed posterior to the distal aorta and surrounded circumferentially just proximal to the iliac bifurcation. This allows for proximal and distal control of the aorta and isolation of the renal circulation. The aorta is cannulated in the pelvis, and once blood circulation has ceased, preservative solution is then perfused through the aortic cannula. The kidneys become pale and cool, and the effluent tends to clear up once the blood has been flushed out.

The kidney is then mobilized around Gerota's fascia. The ureter is identified and care is taken to free the ureter with a pedicle of periureteric fat. The ureter is taken distally as close to the bladder as possible. The ureter receives blood supply from three sources, the renal artery, the gonadal artery, and the internal iliac artery. Due to the lack of a single named artery perfusing the ureter, periureteric fat is essential in maintaining its perfusion when transplanted. Dissection is also limited in the renal hilum. The distal aorta and inferior vena cava are divided and the entire



block is lifted anteriorly to expose the lumbar vessels posteriorly. The proximal aorta and vena cava are then divided and the entire block is removed and placed in a basin with cold preservative solution. At this point, the block consists of bilateral kidneys, ureters, aorta, and inferior vena cava. These may be split into the two individual kidneys for separate packaging, taking care to look for any anatomical variants.

## LIVING DONATION

Living donors are typically worked up and reviewed for suitability by a Selection Committee that must be independent of the recipient team to remove chance of bias in selection. Living donor procurement has increased over the past few decades, especially with the advent of minimally invasive surgical techniques [5]. While most live donor procurements are performed laparoscopically, there have been reports of mini-laparotomy removals and even robotic kidney procurement. In most instances, the left kidney is procured as the vein is much longer and easier to implant.

In order to expose the left kidney, the descending and sigmoid colon are mobilized. The colon is then reflected medially, exposing Gerota's fascia. For right nephrectomy, the hepatic flexure is first mobilized and reflected downwards and medially. The liver is retracted superiorly to expose the superior pole of the kidney. At this point, the right and left nephrectomies follow the same events.

The renal vein is exposed by tracing the gonadal vein cephalad or by bluntly sweeping the perinephric fat away to identify the renal vein. The renal vein is cleared completely and the contributing vessels (gonadal, lumbar, and adrenal) are clipped and ligated. Posteriorly, the artery is exposed and dissected circumferentially. Dissection of the renal artery should take place medial to the gonadal artery in an effort to minimize dissection of the renal hilum. The artery is isolated to the level of the aorta. The superior pole of the kidney is mobilized, dissecting off the adrenal gland, delivering the kidney into the operative field and the posterior attachments are dissected away.

The ureter and mesoureter are separated from the underlying psoas muscle and dissected to the pelvic inlet. At the point where the ureter dives deep into the pelvis, the structures of the ureter and periureteric tissue are hemostatically divided. At this point, the kidney is completely mobilized and tethered by its vascular pedicle only.

An extraction incision is made: 1. Medial to the anterior superior iliac spine as a Pfannenstiel incision, 2. Suprapubic as a transverse incision, or 3. Umbilical as a midline incision. A vascular stapler is introduced and the vascular pedicle is divided individually, the artery is first. Heparin may be given prior to stapling off the artery. Once the kidney is removed, hemostasis is ensured, especially along the staple lines, before the abdomen is deflated and the fascia is closed.

## **BACK TABLE RECONSTRUCTION**

Prior to implantation, back table preparation is required to clean the kidney of perinephric fat, and the adrenal gland in the case of cadaveric donation, which may be adherent. The vessels are dissected clean for a short length to make the anastomosis easier.

In cases of deceased donated kidneys, the kidneys are separated, with an aortic cuff for each kidney. The vena cava is typically left attached to the right kidney due to the short length of the right renal vein, as the left renal vein must traverse the midline of the body and is longer. This allows for back table reconstruction of the vein in donated right kidneys.

The veins may have branches that need ligation, making sure to preserve a single large renal vein. Due to collateralization of the venous system, branches may be ligated without much sequelae and this helps make the venous anastomosis easier. In the case of a cadaveric kidney right renal vein, which is short, reconstructing the vena cava into a tubular structure, which it is usually left attached to during organ procurement, may extend the vein length.

In kidneys with multiple arteries, the arteries may require reconstruction by syndactylizing the lumens of the arteries or anastomosing one branch end-to-side to another so there is a common lumen for anastomosis. In case the bridge between the two arterial lumens is too wide, two separate anastomoses may be necessary. It is important to remember that each artery is typically an end artery with minimal collateralization. Hence it is important to preserve each of the arteries if possible.

## THE RECIPIENT

Kidney allografts are usually transplanted heterotopically in a position which provides easier vascular anastomosis and close proximity to the bladder. The iliac fossa is often recognized as the ideal position [6]. Additionally, kidney allografts may be placed in the retroperitoneum which allows for easy access during allograft biopsies or if percutaneous ureteral intervention is necessary. Orthotopic allograft placement, when the allograft is placed in anatomic position, can also be used after native nephrectomy in select cases. In the case of polycystic kidney disease, the native kidneys must sometimes be removed to make room for the allograft.

An oblique or curvilinear Gibson incision is made on the side of the implantation, in the lower quadrant beginning almost in the midline extending upward in parallel with the inguinal ligament. The external oblique muscle and fascia are then divided. To expose the peritoneum, the internal oblique and transverse muscles are divided or the confluence of the oblique muscles and the rectal sheath is divided medially. The inferior epigastric is often ligated, however in the case of a donor kidney with a lower pole artery; the inferior epigastric artery may be preserved for arterial anastomosis. The spermatic cord is identified in males and retracted lateral with careful attention as to preserve its integrity. The analogous structure in females, the round ligament, does not contain vital structures and can be ligated to improve exposure. The peritoneum is swept upward to expose the iliac vascular system. Lymphatics over these vessels may be ligated to prevent formation of a lymphocele.

The renal artery and vein should be anastomosed in an order to give the surgeon the greatest ease of anastomosis. The renal vein is often anastomosed to the external iliac vein in an end-to-side fashion with continuous 5-0 Prolene suture. Stay-sutures are placed at the midpoint of the anastomosis to provide retraction, lowering any possibility of suturing the back wall during anastomosis. It is important to ensure the renal vein is under no tension and the vein is not twisted before starting the anastomosis.

The arterial anastomosis typically uses the external iliac artery in an end-to-side fashion with a cuff of aorta. After the aortic cuff is trimmed and fitted to the renal artery, the cuff is then anastomosed to the arteriotomy in the external iliac artery. End-to-end anastomosis to the internal iliac artery has also been described.

After revascularization of the kidney, the surgeon then turns to urinary tract reconstruction. The donor ureter's condition and length as well as the recipient's bladder or bladder substitute, condition of the recipient's ureter.

Ureteroneocystostomy is the most typical form of urinary tract reconstruction, often because it does not depend on the recipient's ureter condition and does not disturb the native ureter, it's further from the vascular anastomosis, and does not require a native nephrectomy. An extra vesicalureteroneocystostomy (Lich-Gregoir) technique is often used [7]. In this technique, the bladder is entered through the muscularis to the level of the mucosa, the mucosa is incised and the spatulated ureter is anastomosed to the mucosa. The seromuscular layer is then closed over the ureter, essentially creating the submuscular tunnel to act as an anti-reflux mechanism.

The Politano-Leadbetter technique [8-10] starts with a midline incision in the anterior bladder through all layers. A point clear of the native ureter is selected and a transverse incision is made in the mucosa. A submucosal flap is then made tunneling away from the mucosal incision into the operative field. The donor ureter is then drawn into the bladder through the tunnel. The ureter is then spatulated and anastomosed to the bladder mucosa using fine absorbable suture, the inferior sutures including bladder muscularis to fix the ureter distally. The cystostomy is closed with suture in layers depending on surgeon preference. The bladder is filled to check for leaks.

There are other techniques of ureteral anastomosis described, including the U-stitch or Taguchi technique, which is performed by placing one or two absorbable U-stitches at the distal tip of the ureter. After introduction of the ureter into the bladder, the sutures are brought through the bladder wall, fixing the ureter to the bladder [11]. A ureteroureteral anastomosis is useful if the donor ureter is ischemic or compromised. In this technique, the allograft ureter is spatulated and anastomosed to the native ureter,. The anastomosis can be end-to-side or the native ureter can be ligated and anastomosed in an end-to-end fashion.

If a double ureter is encountered from the donor kidney, the ureters must be preserved. Often, the ureters can be anastomosed in a similar fashion as described in the vascular common trunk above [12]. The ureters can be syndactylized to form a single common ureter . The common ureter can be treated as a single ureter completing the above described ureteroneocystostomy techniques.

Stenting of the ureterovesical anastomosis has been recognized as an independent protective factor in preventing the development of urological complications after kidney transplantation [13]. Ureteric stenting has become more prevalent in kidney transplantation though the debate over routine or selective use continues in the literature. Stenting has been shown in some studies to decrease stenosis though it can be associated with an increased incidence of urinary tract infections without prophylactic antibiotics [14,15]. The use of ureteric stenting in kidney transplantation is largely dependent on surgeon preference.

Pyeloureterostomy is used when the transplanted ureter has compromised blood supply, the urinary bladder is difficult to identify, or when the bladder does not distend enough for a ureteroneocystostomy [9,16,17].

In some situations, urinary system reconstruction involves drainage into an intestinal conduit or intestinal pouch. The anastomosis takes place in the same fashion as the ureteroneocystostomy described above [18,19]. The conduit is externalized in the same fashion as a traditional ostomy, forming an enterocutaneous fistula, which is then managed with a bag collection system attached to the skin.

Closure of the incision takes place in a standard fashion with reapproximation of the tissue in layers. The fascia may be left open if compression of the allograft is a concern.

## **SURGICAL COMPLICATIONS**

Vascular complications have an overall incidence of 2-10% in most series. Arterial complications can include renal artery thrombosis, renal artery stenosis, renal vein thrombosis, or arteriovenous fistula. Arterial thrombosis is usually the consequence of technical or mechanical factors and can be caused by torsion or kinking of the artery, trauma to the donor artery during recovery or reperfusion, disparity in vessel size during anastomosis, or dissection of an intimal flap [20]. The clinical findings suggestive of main renal artery thrombosis include acute allograft tenderness; cessation of urine output or the patient may be asymptomatic. Often, the diagnosis is confirmed with duplex Doppler ultrasound demonstrating absent flow in the renal artery. Thrombectomy or reconstruction may be necessary. In some cases, the graft may be ischemic requiring removal and resumption of renal replacement therapy.

Renal vein thrombosis often occurs early in the postoperative period and often results in loss of the graft. Possible causes of renal vein thrombosis include kinking or angulation of the vein, stenosis of the anastomosis, postoperative hypovolemia, Deep Venous Thrombosis (**DVT**), and renal/iliac vein compression by perinephric fluid collections [21]. Clinically, these patients may present with allograft swelling, pain, oliguria/hematuria, impaired renal function, when renal vein thrombosis is suspected, prompt re-exploration of the allograft with venous thrombectomy is indicated.

The overall incidence of urologic complications after renal transplantation ranges from 0.9-30% in the literature with most centers hovering around 3% incidence or less [22-24]. Unlike the native ureter, the transplanted ureter receives its blood supply from the renal artery only, making preservation of the transplanted renal pelvis of the utmost importance.

Urologic complications can be categorized into two categories: obstruction or extravasation. Obstruction can further be classified as intrinsic or extrinsic. Intrinsic ureteric obstruction is most commonly caused by ischemic ureteric stricture, however can also be caused by post transplant periureteral fibrosis, infection, stones, tumor, blood clot following renal biopsy, and excessive length. The most common site of obstruction is the ureterovesical junction, followed by the distal ureter, mid ureter, and proximal ureter in descending order. Extrinsic obstruction may be caused by fluid collections, commonly lymphocele, hematoma or urinoma. Again, renal ultrasound is often used for diagnosis. The treatment of urologic obstruction often depends on the etiology,

many of which may resolve spontaneously with proximal diversion or stenting. Of note, ureteric strictures can be amenable to balloon dilatation or endoureterotomy [25]. Long strictures greater than 2 cm in length are often best managed with open surgical repair.

Urinary extravasation usually presents early following transplantation. Extravasation from the bladder is more common following the Politano-Leadbetter technique previously described [26]. Presenting symptoms may mimic rejection or obstruction with graft tenderness, fever or decreasing urine output. Cystography should be performed for diagnostic purposes after ruling out obstruction and rejection. In some cases, nuclear scan is necessary to diagnose trace extravasation suggestive of an urinoma or impaired excretion. Small vesicular leaks are managed with Foley catheter drainage and decompression of the bladder. Larger leaks may require operative repair. For leaks above the ureterovesical junction, placement of a percutaneous nephrostomy provides control of urinary leakage, stabilizes the graft function, and prevents expansion of the urinoma. Large urinomas are amenable to percutaneous drainage. If a necrotic ureter is encountered, repeat reconstruction of the urinary system is necessary by an appropriate technique previously described. Additional techniques necessary for reconstruction of the urinary system may include Boari flap, psoas hitch or calyceovesicotomy, which are beyond the scope of this chapter.

Additional complications of renal transplantation include lymphocele, hematoma, abscess or calculi. Most lymphoceles present within the first 2-6 months after renal transplantation and are related to inadequate ligation of perivascular lymphatics during the transplant operation. Most lymphoceles are asymptomatic and are often diagnosed during routine ultrasonography. Clinically significant lymphoceles often present with mass or fullness at the allograft site with signs of ureteric obstruction. In addition to ultrasonography, needle aspiration is useful in diagnosis. Peritoneal window creation is treatment of choice. Other techniques include laparoscopic internal marsupialization [27].

Hematomas account for one-fifth of aspirated perinephric fluid collections and larger hematomas can produce significant local wound and flank pain while causing ureteral obstruction. Typical vital sign changes, including tachycardia or hypotension, may indicate acute blood loss anemia due to a hematoma formation. Additionally, a drop in hemoglobin may be identified along with perinephric rigidity or fullness. Ultrasonography or CT scan will help determine the extent of the hematoma. Management of small hematomas is expectant while larger hematomas require prompt surgical exploration to identify any possible sources of bleeding as well as evacuate the hematoma.

Abscess formation, as in many postoperative patients, typically occurs in the first few days to weeks after renal transplantation. Most late peritransplant abscesses are a consequence of graft pyelonephritis [28]. Other perinephric fluid collections; urinomas, lymphoceles or hematomas, also serve as a source of secondary infection. Ultrasonography and CT scan are the most helpful imaging modalities to detect a peritransplant abscess. Appropriate treatment of peritransplant abscess includes drainage, intravenous antibiotics, and reduction of immune suppression.



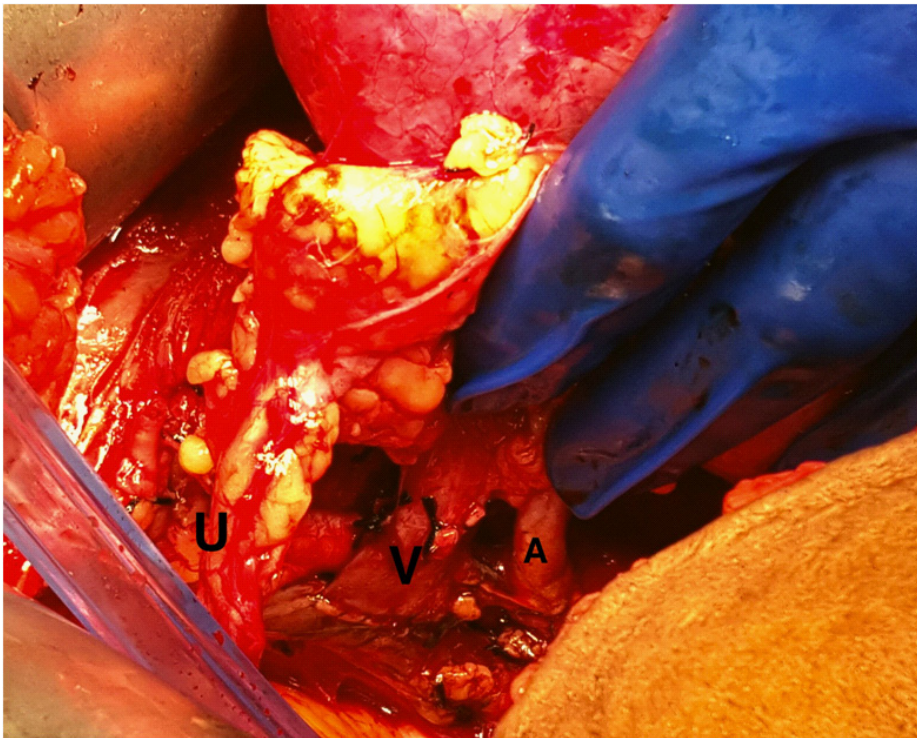


Figure 1: Completed vascular anastomosis in kidney transplantation: A = renal artery to external iliac artery anastomosis, V = renal vein to external iliac vein anastomosis, U = donor ureter with periureteral soft tissue.

## References

1. Merrill JP, Murray JE, Harrison JH. Successful homotransplantations of the human kidney between two identical twins. *JAMA*. 1956;160: 277.
2. Wolfe RA, Ashby VB, Milford EL, et al. Comparison of mortality in all patients on dialysis, patients on dialysis awaiting transplantation, and recipients of a first cadaveric transplant. *N E J M*. 1999; 34;1725.
3. Wyld M, Morton RL, Hayden A, Howard K, Webster AC. A systematic review and meta-analysis of utility-based quality of life in chronic kidney disease treatments. *PLoS Med*. 2012; 9: e1001307.
4. Starzl TE, Hakala TR, Shaw BW Jr, Hardesty RL, Rosenthal TJ. A flexible procedure for multiple cadaveric organ procurement. *Surg Gynecol Obstet*. 1984; 158: 223-230.
5. Clayman RV, Kavoussi LR, Soper NJ, Dierks SM, Merety KS. Laparoscopic nephrectomy. *N Engl J Med*. 1991; 324: 1370-1371.
6. MURRAY JE, MERRILL JP, HARRISON JH. Kidney transplantation between seven pairs of identical twins. *Ann Surg*. 1958; 148: 343-359.
7. Konnak JW, Herwig KR, Turcotte JG. External ureteroneocystostomy in renal transplantation. *J Urol*. 1972; 108: 380-381.
8. Lich R, Howerton LW, David LA. Recurrent urosepsis in children. *J Urol*. 1961; 86: 554.
9. Leadbetter GW Jr, Monaco AP, Russell PS. A technique for reconstruction of the urinary tract in renal transplantation. *Surg Gynecol Obstet*. 1966; 123: 839-841.
10. PAQUIN AJ Jr. Ureterovesical anastomosis: the description and evaluation of a technique. *J Urol*. 1959; 82: 573-583.
11. MacKinnon KJ, Oliver JA, Morehouse DD, Taguchi Y. Cadaver renal transplantation: emphasis on urological aspects. *J Urol*. 1968; 99: 486-490.

12. Conlin MJ, Lemmers MJ, Barry JM. Extravesical ureteroneocystostomy for duplicated allograft ureters. *J Urol.* 1994; 152: 1201-1202.
13. Mangus RS, Haag BW. Stented versus nonstented extravesical ureteroneocystostomy in renal transplantation: a metaanalysis. *Am J Transplant.* 2004; 4: 1889-1896.
14. Georgiev P, Böni C, Dahm F, Maurus CF, Wildi S. Routine stenting reduces urologic complications as compared with stenting "on demand" in adult kidney transplantation. *Urology.* 2007; 70: 893-897.
15. Wilson CH, Bhatti AA, Rix DA, Manas DM. Routine intra-operative ureteric stenting for kidney transplant recipients. *Cochrane Database Syst Rev* CD004925, 2005.
16. HAMBURGER J, CROSNIER J, DORMONT J. EXPERIENCE WITH 45 RENAL HOMOTRANSPLANTATIONS IN MAN. *Lancet.* 1965; 1: 985-992.
17. LAWLER RH, WEST JW, McNULTY PH, CLANCY EJ, MURPHY RP. Homotransplantation of the kidney in the human. *J Am Med Assoc.* 1950; 144: 844-845.
18. Viazzi F, Leoncini G, Derchi LE, Pontremoli R. Ultrasound Doppler renal resistive index: a useful tool for the management of the hypertensive patient. *J Hypertens.* 2014; 32: 149-153.
19. Merion RM, Calne RY. Allograft renal vein thrombosis. *Transplant Proc.* 1985; 17: 1746-1750.
20. Ekelund L, Limdholm T. Arteriovenous fistulae following percutaneous renal biopsy. *ActaRadiol.* 1971;11;38.
21. Salvatierra O Jr, Olcott CIV, Amend WJ Jr et al. Urological complications of renal transplantation can be prevented or controlled. *J Urol*, 1977; 17: 421.
22. Strem SB, Novick AC, Steinmuller DR, Musselman PW. Percutaneous techniques for the management of urological renal transplant complications. *J Urol.* 1986; 135: 456-459.
23. Thrasher JB, Temple DR, Spees EK. Extravesical versus Leadbetter-Politano ureteroneocystostomy: a comparison of urological complications in 320 renal transplants. *J Urol.* 1990; 144: 1105-1109.
24. Ancona E, Rigotti P, Zaninotto G, Comandella MG, Morpurgo E. Treatment of lymphocele following renal transplantation by laparoscopic surgery. *Int Surg.* 1991; 76: 261-263.
25. Kyriakides GK, Simmons RL, Najarian JS. Wound infections in renal transplant wounds: pathogenetic and prognostic factors. *Ann Surg.* 1975; 182: 770-775.
26. Motayne GG, Jindal SL, Irvine AH, Abele RP. Calculus formation in renal transplant patients. *J Urol.* 1984; 132: 448-449.
27. Ancona E, Rigotti P, Zaninotto G, Comandella MG, Morpurgo E. Treatment of lymphocele following renal transplantation by laparoscopic surgery. *Int Surg.* 1991; 76: 261-263.
28. Kyriakides GK, Simmons RL, Najarian JS. Wound infections in renal transplant wounds: pathogenetic and prognostic factors. *Ann Surg.* 1975; 182: 770-775.
29. Alberts VP, Idu MM, Legemate DA, Laguna Pes MP, Minnee RC. Ureterovesical anastomotic techniques for kidney transplantation: a systematic review and meta-analysis. *Transpl Int.* 2014; 27: 593-605.