

# Thrombocytopenia Due to Thrombotic Thrombocytopenic Purpura or Atypical Hemolytic Uremic Syndrome: from Syndromes to Diseases

**Han-Mou Tsai<sup>1\*</sup>**

<sup>1</sup>iMAH Hematology Associates, New Hyde Park, USA

**\*Corresponding author:** Han-Mou Tsai, iMAH Hematology Associates, New Hyde Park, New York, USA, Email:

hmtsai@gmail.com

**Published Date:** April 30, 2016

## ABSTRACT

Many diseases are first recognized as a syndrome or a collection of symptoms and signs that are presumed to be the consequence of a particular etiology or disease mechanism. This process works for many syndromes but can be confusing or misleading when the syndrome actually results from more than one disease with vastly different etiology or mechanism. This review discusses how the syndrome of Microangiopathic Hemolytic anemia (**MAHA**) and thrombocytopenia has evolved from vaguely defined 'TTP', 'TTP/HUS' or 'TTP/TMA' to a collection of diseases that include, among others, mechanistically defined thrombotic thrombocytopenic purpura (**TTP**) and Atypical Hemolytic Uremic Syndrome (**AHUS**). These two diseases account for the majority of patients presenting with the syndrome of MAHA and thrombocytopenia. Nevertheless, they may also present without either MAHA or thrombocytopenia. These advances highlight the need for a new scheme of disease classification and provide the basis for a more rational approach to the diagnosis and management of TTP and AHUS.

**Key words:** Thrombotic thrombocytopenic purpura; Atypical hemolytic uremic syndrome; Microangiopathic hemolytic anemia; Complement; ADAMTS13.

Down observed in 1866 that ‘Those who have any given attention to congenital mental lesions must have been frequently puzzled how to arrange, in any satisfactory way, the different classes of this defect which may have come under their observation’ [1].

Such frustration applies just as fittingly to the syndrome of Microangiopathic Hemolytic Anemia (**MAHA**) and thrombocytopenia. Patients presenting with the syndrome of MAHA and thrombocytopenia (MAHA/T) have been given variably the diagnosis of Thrombotic Thrombocytopenic Purpura (**TTP**), Hemolytic Uremic Syndrome (**HUS**), TTP/HUS or TTP/TMA (thrombotic microangiopathy). Almost invariably the criteria for these diagnostic terms are vague, artificial or overlapping.

A serious consequence of indiscriminate usage of diagnostic terms is that all patients presenting with the syndrome of MAHA/T have been treated as one disease with plasma exchange, supplemented with anti-platelet agents, corticosteroids, immunosuppressive drugs, and even splenectomy. On the other hand, the correct diagnosis is missed for patients who do not have MAHA, thrombocytopenia or both.

## **DIFFERENCE BETWEEN A SYNDROME AND A DISEASE**

Many diseases are first recognized as a syndrome, which is simply a particular collection of symptoms or signs. It is commonly assumed that a syndrome is the consequence of a particular disease etiology or pathogenesis. When the etiology of the syndrome is identified, it becomes a disease, although often under the same or similar term. The discovery of the etiology allows exclusion of patients with whose similar features are due to other etiologies or mechanisms and identification of patients atypical features of the disease. Almost invariably the disease is found to be more variable in manifestations than previously recognized. Down syndrome took this path after the discovery of trisomy 21 in 1959 as its cause [2].

Unfortunately, not all syndromes are due to one particular etiology or pathogenesis. ‘TTP’ or ‘TTP/HUS’, defined as a syndrome of MAHA and thrombocytopenia, is a conspicuous example of how syndrome-based disease definition may go seriously astray. Until recently, ‘TTP’ or ‘TTP/HUS’ has been a source of much confusion and uncertainty. Some have tried to rectify the confusion by adding criteria such as young age and severe renal dysfunction for atypical HUS, and fever and neurologic deficits for TTP. The adoption of any particular set of criteria is inevitably arbitrary and does not resolve the inherent uncertainty of epiphenomena-based approach to disease definition.

## **FROM SYNDROMES TO DISEASES**

A subset of the patients presenting with the syndrome of MAHA/T have a prodrome of hemorrhagic diarrhea and are often afflicted with prominent renal failure [3]. This subset of patients, previously given the diagnosis of typical or diarrhea+ hemolytic uremic syndrome (D+HUS), were first identified in young children. At autopsy, the patients were found to have the

pathology of Thrombotic Microangiopathy (**TMA**), which is characterized with endothelial injury and thrombosis in the small arteries, arterioles and glomerular capillaries of kidney [4].

The hemorrhagic diarrhea of D+HUS has been demonstrated in most cases to result from colitis due to infection of Shiga toxin producing *E. coli*, most commonly but not invariably serotype O157:H7 [5]. Subsequent analysis of stools for Shiga toxins or Shiga toxin-producing *E. coli* show that not all cases with the infection have obvious hemorrhagic diarrhea before they go on to develop TMA and its various clinical complications. Furthermore, some patients develop TMA following such an infection do not have MAHA or thrombocytopenia; and the severity of renal insufficiency may be mild.

To encompass these forme fruste cases, the syndrome of D+HUS is replaced with the disease of Shiga toxin associated HUS (STX-HUS), defined as TMA following infection with shiga toxin-producing microorganisms. This etiologically defined disease includes most of the cases previously given the diagnosis of typical or D+HUS. It also includes the forme fruste cases that do not have MAHA, thrombocytopenia, severe renal injury, or a prodrome of hemorrhagic diarrhea.

In children, the syndrome of MAHA/T, often accompanied with prominent renal dysfunction, also occurs without antecedent hemorrhagic diarrhea or Shiga toxin associated colitis. Such cases were given the diagnosis of Atypical Hemolytic Uremic Syndrome (**AHUS**). The cases may be sporadic or familial affecting multiple members of a family.

In contrast, most adult cases presenting with the syndrome of MAHA/T do not have a prodrome of hemorrhagic diarrhea or evidence of infection with a Shiga toxin producing microorganism. The kidney function is not or only minimally affected in most cases. Such cases have been given the diagnosis of Thrombotic Thrombocytopenic Purpura (TTP). In a small fraction of the adult cases, renal dysfunction may be severe. Such cases are not dissimilar to pediatric cases of aHUS. Yet these adult patients are often given the diagnosis of TTP or TTP/HUS, based on the misconstrued belief that AHUS only occurs in children and the small numbers of adult cases that do develop severe renal dysfunction merely have TTP with exceptionally severe renal injury.

In recent years, ADAMTS13, a circulating metalloprotease, was identified and cloned during research to understand how the von Willebrand factor (VWF) multimers in normal plasma are generated [6]. In the circulation, ADAMTS13 prevents the activation of VWF by cleaving the large polymeric protein whenever its conformation is being unfolded and activated by shear stress. Deficiency of ADAMTS13, due to inhibitory auto-antibodies or genetic mutations, is found in essentially all patients who are given the diagnosis of 'TTP' but do not have serious renal dysfunction (maximal serum creatinine <2.5 mg/dl) or a comorbidity such as disseminated intravascular coagulopathy, pneumococcal sepsis, pregnancy, autoimmunity with positive ANA tests, hematopoietic stem cell therapy or chemotherapeutic drugs [7,8].

Separately, defective regulation of the alternative complement pathway has been found in many children given the diagnosis of 'AHUS' and adults with the syndrome of MAHA/T and severe renal injury [9]. Together, these findings show that 'TTP' with ADAMTS13 deficiency and

'AHUS' with defective regulation of the alternative complement pathway, account for most cases of MAHA/T without comorbid conditions.

## DIFFERENCE IN PATHOLOGY

Comparison of the pathological features of patients with ADAMTS13 deficiency and those with defective regulation of the alternative complement pathway further reveals that these two disorders are also quite different in pathology [10]. TTP is associated with widespread VWF rich platelet thrombosis in arterioles and capillaries of multiple organs; whereas aHUS is associated mainly with TMA in the kidney.

A review of the literature shows that clinicians often use the term 'TMA' synonymously with the syndrome of MAHA and thrombocytopenia. This usage implies, incorrectly, that a patient presenting with MAHA/T have endothelial injury (microangiopathy) and thrombosis in small vessels and vice versa. On the other hand, pathologists often use the term of TMA for any lesions with microvascular thrombosis, even in patients without MAHA and thrombocytopenia.

To avoid confusion, TMA should be used only for the pathological syndrome of endothelial injury (microangiopathy) and thrombosis in small vessels, as are found in STX-HUS and AHUS. In 'TTP' with ADAMTS13 deficiency, the cardinal pathologic feature is VWF-rich platelet thrombi in arterioles and capillaries, accompanied with no or minimal evidence of endothelial injury. Thus, not only TTP with ADAMTS13 deficiency and AHUS with defective complement regulation are different in pathogenesis, they are also quite different in pathology. The two diseases have been intertwined because they both often present MAHA and thrombocytopenia.

## EXPANDING SPECTRA OF DISEASE PRESENTATIONS

The molecular tests developed in research have been translated to clinical practice. Unsurprisingly, these tests have begun to identify patients that have ADAMTS13 <10% or mutations affecting ADAMTS13 the regulation of alternative complement pathway but do not have MAHA, thrombocytopenia, or both, although some of these patients do have MAHA and thrombocytopenia on other occasions. Such patients should be considered to have TTP or AHUS and managed accordingly.

The tests also identify individuals with ADAMTS13 deficiency or defective regulation of the alternative complement pathway but have never been ill. These asymptomatic patients would be excluded from the conventional syndrome-based diagnosis of 'TTP' or 'AHUS' until they present with both MAHA and thrombocytopenia later in life. This practice is analogous to excluding the diagnosis of sickle cell anemia for a patient who has the hemoglobin  $\beta^S\beta^S$  genotype but has not experienced a painful crisis.

Both asymptomatic individuals and those with incomplete presentations likely have milder forms of their diseases and thus require stronger triggers to precipitate widespread VWF-platelet thrombosis or serious uncontrolled complement activation. Diagnosis of TTP or AHUS before any

or all complications occur provides the best opportunity to protect the individuals from serious and sometimes fatal consequences of the disease.

To encompass such forme fruste cases, it is necessary to re-define TTP and AHUS as etiology/pathogenesis-based diseases (Table 1). The difference between mechanistically defined TTP and AHUS is further delineated in Table 2.

**Table 1:** Two approaches to defining TTP and HUS.

Syndrome-based definitions
<ul style="list-style-type: none"> <li>• TTP: MAHA and thrombocytopenia (diad); Diad plus neurological deficits(triad); or triad plus renal abnormalities and fever (pentad)</li> <li>• Typical or D+ HUS: renal failure, MAHA and thrombocytopenia after a prodrome of hemorrhagic diarrhea</li> <li>• Atypical or D- HUS: renal failure, MAHA and thrombocytopenia without a prodrome of hemorrhagic diarrhea</li> </ul>
<p><i>Pros</i></p> <ul style="list-style-type: none"> <li>- The diagnostic criteria are readily available in clinical practice</li> </ul> <p><i>Cons</i></p> <ul style="list-style-type: none"> <li>- The severity of renal failure for diagnosis of AHUS is uncertain</li> <li>- The criteria do not clearly distinguish TTP, D+HUS or D-HUS from one another or other causes of MAHA/T in some cases</li> <li>- The criteria do not encompass patients without MAHA, thrombocytopenia or both.</li> </ul>
Etiology/mechanism-based definitions
<ul style="list-style-type: none"> <li>• TTP: a disorder with predisposition to arteriolar and capillary thrombosis due to inhibitory antibodies or mutations of ADAMTS13</li> <li>• STX-HUS: a disorder with TMA due to infection with shiga toxin producing microorganisms</li> <li>• AHUS: a disorder with predisposition to TMA due to defective regulation of the alternative complement pathway</li> </ul>
<p><i>Pros</i></p> <ul style="list-style-type: none"> <li>- Each disease is mechanistically or etiologically distinctive</li> <li>- They do not rely on arbitrary thresholds of anemia, thrombocytopenia or renal failure</li> <li>- They include patients without MAHA, thrombocytopenia, neurological deficits, or renal failure</li> </ul> <p><i>Cons</i></p> <ul style="list-style-type: none"> <li>- Laboratory tests for diagnosis of TTP (ADAMTS13 activity and inhibitor) and AHUS (gene sequencing of CFH, CD46, CFI, CFB, C3 and THBD; and ELISA for CFH antibodies) may not be readily available</li> </ul>

*Abbreviations:* ADAMTS13- a disintegrin and metalloprotease with thrombospondin type 1 repeats, member 13; AHUS- atypical hemolytic uremic syndrome; CFB- complement factor B; CFH- complement factor H; CFI- complement factor I; D+- diarrhea positive; D-- diarrhea negative; HUS- hemolytic uremic syndrome; MAHA/T- microangiopathic hemolytic anemia and thrombocytopenia; STX- Shiga toxins; THBD, thrombomodulin

**Table 2:** A comparison of TTP with AHUS.

Disease	TTP		AHUS	
	Genetic	Autoimmune	Genetic	Autoimmune
<b>Age of presentation</b>	Infancy-early childhood; less commonly thereafter	Adolescence-adulthood; uncommon <10 years of age	Infancy-adulthood	
<b>Pathogenesis</b>	Severe deficiency of ADAMTS13 (<10%)		Defective regulation of the alternative complement pathway	
	Genetic mutations	Inhibitory antibodies of ADAMTS13	Genetic mutations	Antibodies of CFH
<b>Pathology</b>	VWF-rich platelet thrombi in arterioles and capillaries		Thrombotic microangiopathy (Endothelial injury and thrombosis)	
<b>Pathophysiology of complications</b>	<ul style="list-style-type: none"> <li>• Thrombotic ischemia                             <ul style="list-style-type: none"> <li>–Brain and eye: altered mental status, focal deficits, visual defects</li> <li>–Kidney: hematuria, renal insufficiency (maximal Cr &lt; 2.5 mg/dl)<sup>1</sup></li> <li>–Heart: myocardial injury, electrical-mechanical dissociation, arrhythmia</li> <li>–Pancreatitis</li> </ul> </li> <li>• Thrombocytopenia: platelet consumption</li> <li>• MAHA: mechanical injury of RBC</li> </ul>		<ul style="list-style-type: none"> <li>• Renal failure:                             <ul style="list-style-type: none"> <li>–Direct glomerular injury by MAC</li> <li>–Ischemic injury (thrombotic and/or non-thrombotic)</li> </ul> </li> <li>• Hypertension: dysregulated renin release</li> <li>• Extra-renal complications: abnormal vascular permeability<sup>5</sup></li> <li>• Thrombocytopenia: platelet consumption</li> <li>• MAHA: mechanical injury of RBC</li> </ul>	
<b>Laboratory diagnosis</b>	Plasma ADAMTS13 activity <10%		Gene sequencing: CFH, CD46, CFI, CFB, C3, THBD	Antibodies of CFH
	No inhibitors <sup>2</sup>	Inhibitors <sup>2</sup>		
<b>Acute treatment</b>	Plasma infusion <sup>3</sup>	Plasma exchange	Anti-complement therapy with eculizumab	
	Recombinant ADAMTS13 <sup>4</sup>			
<b>Long-term treatment</b>	Plasma infusion every 2-3 weeks for most cases	ADAMTS13-guided rituximab	<ul style="list-style-type: none"> <li>• Anti-complement therapy</li> <li>• Monitoring of early symptoms</li> </ul>	
<b>Prognosis</b>	<ul style="list-style-type: none"> <li>• &gt;90% fatal if not treated</li> <li>• Good if treated promptly and appropriately</li> </ul>		<ul style="list-style-type: none"> <li>• &gt;50% ESRD or death (with or without plasma therapy)</li> <li>• Good with prompt anti-complement therapy</li> </ul>	

<sup>1</sup>Renal insufficiency can be more serious in genetic ADAMTS13 deficiency. <sup>2</sup>ADAMTS13 inhibitors are only detected in 80%-90% of patients with the inhibitors. When inhibitors are not detected, refers to Figure 1 for distinction between hereditary and autoimmune TTP. <sup>3</sup>Plasma exchange if the patient has renal failure with impaired urine output. <sup>4</sup>Under development. <sup>5</sup>Abnormal vascular permeability may present as posterior reversible encephalopathy syndrome (PRES) of the brain; edema of brain, retina, bronchial wall, alveoli, intestinal wall, mesentery, pancreas and/or cutaneous soft tissues; and fluids in pleural, pericardial and/or peritoneal cavities.

**Abbreviations:** ADAMTS13- a disintegrin and metalloprotease with thrombospondin type 1 repeat, member 13; AHUS- atypical hemolytic uremic syndrome; CFB, CFH, and CFI- complement factors B, H and I; ESRD- end stage renal disease; MAC- membrane attack complex (C5b-9); THBD- thrombomodulin; TTP,- thrombotic thrombocytopenic purpura

# PATHOPHYSIOLOGY

The complications of TTP include thrombocytopenia, due to platelet consumption in thrombosis; MAHA, due to mechanical injury of the red blood cells in the stenotic microvasculature; and ischemic dysfunctions of organs such as brain, heart and kidney that are affected with microvascular thrombosis (Table 2).

The complications of AHUS include, in addition to renal failure, MAHA and thrombocytopenia, hypertension and extra-renal manifestations (Table 2). Renal failure in AHUS may result from direct glomerular injury by C5b-9 (a.k.a. membrane attack complex, MAC) or ischemic injury due to microvascular stenosis, which may be caused by thrombosis, non-thrombotic endothelial swelling and sub-endothelial expansion, or both.

MAHA results from injury and fragmentation of red blood cells by abnormal levels of shear stress in stenotic or thrombotic arterioles. Thrombocytopenia reflects consumption of platelets in thrombosis. Hypertension is the consequence of dysregulated renin release from juxtaglomerular cells due to disruption of peri-glomerular hemodynamics. Hence MAHA and thrombocytopenia are common in AHUS as well as in TTP.

Extra-renal manifestations of AHUS such as headache, visual defects, altered consciousness or mental status, seizures, dyspnea, chest pain, abdominal pain, anorexia, nausea, vomiting, soft tissue swelling and sudden death are associated with Posterior Reversible Encephalopathy Syndrome (**PRES**) of the brain; exudates, ischemia and sometimes thrombosis of retinal arterioles; edema of brain, bronchial wall, alveoli, intestinal wall, mesentery, pancreas and/or cutaneous soft tissues; and fluids in pleural, pericardial and/or peritoneal cavities. These abnormalities are believed to result from abnormal vascular permeability, presumably induced by anaphylatoxins C3a and C5a of complement activation.

In AHUS, the pathology of TMA is found primarily in the kidney. It is assumed that the microenvironment of the kidney, with varying pH and ionic strength, is conducive to complement activation. Anaphylatoxins are likely released from the kidney to cause histamine secretion from basophils and tissue mast cells. This may explain why extra-renal manifestations of AHUS are not associated with TMA in the affected tissues or organs, often abate with the development of end stage renal disease, and relapse after kidney transplantation.

# ASSESSING DISEASE ACTIVITY

Because of difference in pathophysiology, the five groups of complications in AHUS are not always present and often do not parallel each other. In fact, it is not uncommon to encounter patients with worsening renal failure and extra-renal complications yet stable platelet counts. Death may occur from brain edema and herniation with the platelet count only mildly or moderately decreased. None of the five groups of complications alone can be relied upon for representation of disease activity in AHUS. This is quite different from TTP, in which the platelet count provides reliable representation of the disease activity in most cases.

Laboratory tests such as C3a, C5a and soluble MAC have been used for detection of complement activation. Nevertheless, the sensitivity and reliability of these tests in representing complement activation and disease activity of AHUS remain to be rigorously investigated.

## **MAHA/T MAY RESULT FROM OTHER TYPES OF PATHOLOGY**

Overall, five different types of pathology have been associated with MAHA and thrombocytopenia (**Table 3**). The pathological lesions share the common feature of arteriolar stenosis, which, by generating abnormal levels of shear stress, causes mechanical injury and fragmentation of red blood cells. Thrombocytopenia often accompanies MAHA because platelets are consumed in thrombosis, the most common cause of arteriolar stenosis. In diseases with non-thrombotic arteriolar stenosis, thrombocytopenia may occur via other mechanisms such as immune thrombocytopenia in autoimmune vasculitis or decreased megakaryopoiesis due to bone marrow metastasis in patients with tumor cell embolism.

TTP and AHUS (60% and 20% respectively) together account for the majority of cases presenting with MAHA/T [11]. However, these figures are not to be taken literally, as the distribution may be skewed by referral cases. The incidence of STX-HUS is likely to vary widely, depending on geographic locations and occurrence of outbreaks. The HELLP syndrome, the most cause of MAHA and thrombocytopenia during pregnancy, may account for a larger fraction of the cases at institutions with large obstetric services. The incidence of MAHA/T also varies widely following hematopoietic stem cell therapy [12,13].

Not included in Table 3 are intravascular devices such as ventricular assist devices, prosthetic heart valves and extracorporeal membrane oxygenators that are also commonly associated with hemolysis due to mechanical injury of red blood cells.



**Table 3:** A pathological classification of disorders of MAHA and thrombocytopenia based.

MAHA/T is a common mode of presentation	MAHA/T is an uncommon mode of presentation
<i>1. Thrombotic microangiopathy</i>	
- AHUS	<ul style="list-style-type: none"> <li>- Infection with Shiga toxin producing microorganisms</li> <li>- Sepsis due Neuraminidase producing <i>S. pneumoniae</i></li> <li>- Anti-VEGF drugs</li> <li>- Chemotherapeutic and other drugs</li> <li>- DGKE nephropathy</li> <li>- Cobalamin C disease</li> <li>- Malignant hypertension (?)</li> </ul>
<i>2. VWF-platelet thrombosis</i>	
- TTP	- (None)
<i>3. Fibrin-platelet thrombosis</i>	
- HELLP syndrome of pregnancy (presumably associated with hepatic sinusoidal endothelial injury)	<ul style="list-style-type: none"> <li>- DIC</li> <li>- Anti-phospholipid antibody syndrome</li> <li>- Heparin induced thrombocytopenia</li> <li>- Paroxysmal nocturnal hemoglobinuria</li> </ul>
<i>4. Vasculitis/vasculopathy</i>	
- (None)	<ul style="list-style-type: none"> <li>- Vasculopathy of renal scleroderma</li> <li>- Immune complex or ANCA mediated vasculitis</li> <li>- Rocky mountain spotted fever</li> <li>- Fungemia, viremia</li> <li>- Malignant hypertension (?)</li> </ul>
<i>5. Tumor cell embolism (intravascular clusters of tumor cells)</i>	
- (None)	- Metastatic neoplastic diseases

*Abbreviations:* AHUS- atypical hemolytic uremic syndrome; ANCA- anti-neutrophil cytoplasmic antibody; DGKE- diacylglycerol kinase epsilon; DIC- disseminated intravascular coagulopathy; HELLP- hemolysis, elevated liver enzymes and low platelet count; MAHA/T- microangiopathic hemolytic anemia and thrombocytopenia; VEGF- vascular endothelial growth factor.

## TTP IN DIFFERENTIAL DIAGNOSIS

Most cases of TTP are diagnosed when the patients present with thrombocytopenia and MAHA, especially at its very first presentation. Neurological abnormalities such as altered mental status or focal deficits are common but not invariably present. Fever occurs when the disease is advanced. The kidney function is normal or only mildly impaired in most cases. Nevertheless, advanced renal failure does not exclude TTP because it may result from a concurrent disorder such as STX-HUS [14], complement factor H mutation [15], or anti-glomerular basement membrane nephropathy (a personal unpublished case).

With close monitoring after they achieve remission, more patients are noted to develop thrombocytopenia before MAHA and symptoms occur during relapses. Thus, it should not be unexpected that occasionally, de novo cases of TTP may present as ‘idiopathic thrombocytopenia’, without MAHA, neurologic deficits or renal abnormalities. TTP should be suspected when a patient who appears to be a case of ‘idiopathic thrombocytopenic purpura (ITP)’ also has symptoms such as fatigue, headache or dizziness that is not otherwise explainable (Table 4).

**Table 4:** Conditions in which TTP or AHUS should be suspected.

TTP
<ul style="list-style-type: none"> <li>• Diad (MAHA/T), triad (diad + neurological deficits), or pentad (triad + renal abnormality and fever)</li> <li>• Thrombocytopenia with fatigue or non-specific CNS symptoms (e.g. headache, dizziness)</li> <li>• Stroke or myocardial infarction with thrombocytopenia of no apparent causes</li> <li>• Stroke or myocardial infarction with a history of TTP</li> <li>• Thrombocytosis with MAHA (smoldering TTP)</li> </ul>
AHUS
<ul style="list-style-type: none"> <li>• Renal insufficiency with MAHA, thrombocytopenia, and/or systemic abnormal vascular permeability without comorbid conditions</li> <li>• Idiopathic severe or malignant hypertension, particularly when it is associated with renal insufficiency, MAHA, thrombocytopenia, and/or systemic abnormal vascular permeability</li> <li>• TMA in kidney biopsy               <ul style="list-style-type: none"> <li>- Other causes of TMA (Table 3) should be excluded</li> </ul> </li> <li>• Renal failure of unknown etiology, before renal transplantation</li> </ul>
Comorbid conditions in which MAHA and thrombocytopenia may result from AHUS
<ul style="list-style-type: none"> <li>• Febrile illnesses, inflammation, surgery, trauma, or intravenous radiographic contrast media</li> <li>• Hematopoietic stem cell therapy               <ul style="list-style-type: none"> <li>- Drug-associated TMA or vasculopathy due to viremia or fungemia should be excluded</li> <li>- AHUS may result from antibodies of complement factor H, or less commonly, genetic mutations</li> </ul> </li> <li>• Autoimmunity with positive ANA, ANCA or antiphospholipid antibodies               <ul style="list-style-type: none"> <li>- Kidney biopsy is often necessary to distinguish TMA from fibrin-platelet thrombosis, vasculopathy and vasculitis</li> </ul> </li> <li>• Pregnancy               <ul style="list-style-type: none"> <li>- Preeclampsia/HELLP syndrome is the most common cause of hypertension, MAHA and thrombocytopenia during pregnancy</li> <li>- Preeclampsia/HELLP may transition to AHUS in patients with defects in complement regulation</li> <li>- AHUS should be suspected when renal failure is more than mild or persists, worsens or occurs after delivery</li> </ul> </li> </ul>

*Abbreviations:* ANA- anti-nuclear antibodies; ANCA- anti-neutrophil cytoplasmic antibodies; CNS- central nervous system; HELLP- hemolysis, elevated liver enzymes and low platelet counts; MAHA/T- microangiopathic hemolytic anemia and thrombocytopenia; TMA- thrombotic microangiopathy; STX-HUS- shiga toxin associated hemolytic uremic syndrome; TTP- thrombotic thrombocytopenic purpura; VEGF- vascular endothelial growth factor.

TTP should also be suspected when a patient presenting with stroke or myocardial infarction has history of TTP or a decrease of the platelet count from baseline levels that cannot be attributed to other causes. Uncommonly, smoldering TTP may present with thrombocytosis due to excessive compensatory thrombocytopoiesis.

## CONFIRMING THE DIAGNOSIS OF TTP

When TTP is suspected, the diagnosis can be confirmed by ADAMTS13 analysis. The analysis includes plasma ADAMTS13 activity and inhibitors of ADAMTS13. With a reliable assay, the plasma ADAMTS13 activity is  $\leq 10\%$  in patients who have active platelet consumption. On the other hand, a patient can also be in clinical remission with ADAMTS13  $\leq 10\%$ . When ADAMTS13 activity is greater than 10%, VWF-platelet aggregation and microvascular thrombosis do not occur. A plasma ADAMTS13 activity  $>10\%$  during periods of persisting thrombocytopenia or declining platelet counts excludes TTP as the cause of the thrombocytopenia or decreasing platelet counts.

A plasma ADAMTS13 activity  $>10\%$  but  $<20\%$  (based on the mean level of the patients with MAHA and thrombocytopenia due to other causes minus 3 standard deviations), is also likely to signify TTP. Such levels are most commonly observed in TTP patient who have received transfusion of blood products before the testing, but also occasionally in TTP patients undergoing spontaneous remission.

Detection of ADAMTS13 inhibitors support the diagnosis of acquired TTP due to autoimmunity of ADAMTS13. However, since the sensitivity of inhibitor assays is in the range of 80%-90%, a negative inhibitor assay result does not exclude the diagnosis of autoimmune TTP.

When inhibitors are not detected, further information is needed to distinguish between hereditary and acquired TTP. Findings that favor the diagnosis of hereditary TTP include age of initial presentation during infancy and partial deficiency in first degree relatives. Conversely, plasma ADAMTS13 levels that increase less than expected after plasma therapy or recover to greater than 15% during remission favor the diagnosis of acquired TTP due to autoimmunity of ADAMTS13.

Plasma ADAMTS13 activity may be decreased in a variety of pathological conditions such as sepsis, DIC, cirrhosis and multiorgan failures. The plasma ADAMTS13 activity level also decreases during pregnancy, especially when it is complicated with the HELLP (hemolysis, elevated liver enzymes and low platelet counts) syndrome [16,17]. However, the plasma ADAMTS13 level in these pathological and physiological conditions does not decrease below 10% of normal to cause microvascular VWF-platelet thrombosis of TTP. Spuriously low ADAMTS13 activity results may occur if the blood samples are not properly handled and processed.

## AHUS IN DIFFERENTIAL DIAGNOSIS

Most cases of AHUS are suspected when the patients present with the triad of renal insufficiency, MAHA and thrombocytopenia. The renal insufficiency is often but not invariably severe - it can

also be mild, especially initially. Therefore, the severity of renal function impairment does not reliably distinguish AHUS from TTP. Other conditions that should raise the possibility of AHUS are listed in Table 4.

In patients without severe ADAMTS13 deficiency and comorbid conditions, AHUS is the presumptive diagnosis for those presenting with renal insufficiency of any severity accompanied with MAHA, thrombocytopenia and/or systemic abnormal vascular permeability. TMA in kidney biopsy further supports the diagnosis.

However, AHUS is not the only cause of TMA. Other causes of TMA should be excluded. These include STX-HUS, neuraminidase-HUS in association with pneumococcal or other causes of sepsis, anti-vascular endothelial growth factor drugs, chemotherapeutic drugs, DGKE (diacylglycerol kinase epsilon) nephropathy and cobalamin C disease [18-21] (Table 3). DGKE nephropathy typically presents during infancy or early childhood and tends to be associated with prominent proteinuria. Only rarely does cobalamin C disease present as idiopathic TMA.

Severe or malignant hypertension is often believed to cause the syndrome of MAHA and thrombocytopenia and the pathology of TMA [22-24]. Nevertheless, some of the cases are found in retrospect to have AHUS [9]. AHUS may even present as severe or malignant hypertension without MAHA, thrombocytopenia or renal failure [25]. AHUS should be suspected in cases of hypertension that is severe but labile or associated with progressive deterioration of renal function or extra-renal complications of abnormal vascular permeability.

When a patient with end stage renal disease due to AHUS undergoes kidney transplantation, the risk of recurrent TMA and graft loss is very high. The graft loss can be prevented with anticomplement therapy. Therefore, the possibility of AHUS should be excluded or monitored closely when the cause of renal failure is unknown for a candidate of undergoing kidney transplantation.

## **AHUS IN PATIENTS WITH COMORBID CONDITIONS**

Certain conditions such as febrile illnesses, inflammation, surgery, trauma, or intravenous radiographic contrast agents are not known to directly link to microvascular stenosis or thrombosis but may trigger complement activation and the development of TMA in patients with defective regulation of the alternative complement pathway.

In other comorbid conditions such as hematopoietic stem cell therapy, pregnancy, or autoimmunity with positive antinuclear antibodies, antineutrophil cytoplasmic antibodies or antiphospholipid antibodies, renal insufficiency with MAHA and/or thrombocytopenia may result from AHUS or other mechanisms. AHUS is the presumptive diagnosis after other potential causes are excluded (Table 4).

In patients who do not require immunosuppression for graft versus host disease after hematopoietic stem cell therapy, deranged recovery of the immune system may lead to the

generation of antibodies of CFH and hence AHUS. The complications of AHUS may appear a few weeks to several months after myeloablation or discontinuation of immunosuppressive drugs [13,26]. Such post-immunosuppression autoimmunity can also lead to the development of inhibitory autoantibodies of ADAMTS13 and hence acquired TTP.

For most patients presenting with renal insufficiency, MAHA and thrombocytopenia and are found to have positive antinuclear antibodies, antineutrophil cytoplasmic antibodies, or antiphospholipid antibodies but no severe ADAMTS13 deficiency, kidney biopsy is often needed to distinguish TMA from other types of pathology such as vasculopathy (e.g, renal scleroderma), vasculitis, and microvascular fibrin-platelet thrombosis (e.g, catastrophic antiphospholipid antibody syndrome) .

During pregnancy, the HELLP syndrome is the most common cause of MAHA and thrombocytopenia. On the other hand, activation of the complement system during pregnancy [27], can trigger the development of TMA in patients with preexisting defective regulation of the alternative complement pathway. If such women happen to have preeclampsia or the HELLP syndrome, the transition to AHUS may be mistaken to be persisting or worsening HELLP syndrome. Inclusion of AHUS may account for the high prevalence (~10%) of AHUS mutations in clinical series of preeclampsia/HELLP [28]. AHUS should be suspected when renal failure is severe or presumed 'preeclampsia/HELLP' persists, worsens or occurs after delivery.

## CONFIRMING THE DIAGNOSIS OF AHUS

The diagnosis of AHUS is confirmed by mutation analysis of regulators of the alternative complement pathway, which includes Complement Factor H (**CFH**), CD46 (aka membrane cofactor protein, MCP), Complement Factor I (**CFI**), and Thrombomodulin (**THBD**) and ELISA for antibodies of CFH. Mutation analysis also includes Complement Factor B (**CFB**) and C3, since gain of function mutations of either protein may disrupt the regulation of the alternative complement pathway

The laboratory tests for confirmation of AHUS are not yet optimal. The tests only identify 40% - 75% of patients that are known to have defective regulation of the alternative complement pathway. Negative test results do not exclude the diagnosis of AHUS. Furthermore, these tests may have turnaround times of weeks to months. Therefore, for patients presenting with acute complications, therapeutic decisions are made in most cases when the diagnosis of AHUS is only presumptive.

## A SYSTEMIC APPROACH TO THE DIFFERENTIAL DIAGNOSIS OF MAHA AND THROMBOCYTOPENIA

For patients presenting with the syndrome of MAHA and thrombocytopenia, a complete history and physical examination are essential. In addition, plasma ADAMTS13 analysis, DIC panel, lupus anticoagulants and autoimmune serology should be obtained immediately (Figure 1, 1). Stool

shiga toxin analysis should be requested for patients in endemic areas, particularly when there is recent diarrhea or impaired renal function.

A plasma ADAMTS13 activity less than 10% of normal, when reliably performed, constitutes the diagnosis of TTP (②). A positive ADAMTS13 inhibitor assay is diagnostic of acquired (autoimmune) TTP (③). When the ADAMTS13 inhibitor assay is negative (④), a distinction between acquired and congenital TTP will require further investigation, which includes ADAMTS13 activity during remission, ADAMTS13 response to plasma therapy, age of initial presentation, and/or family studies (⑤ and ⑥).

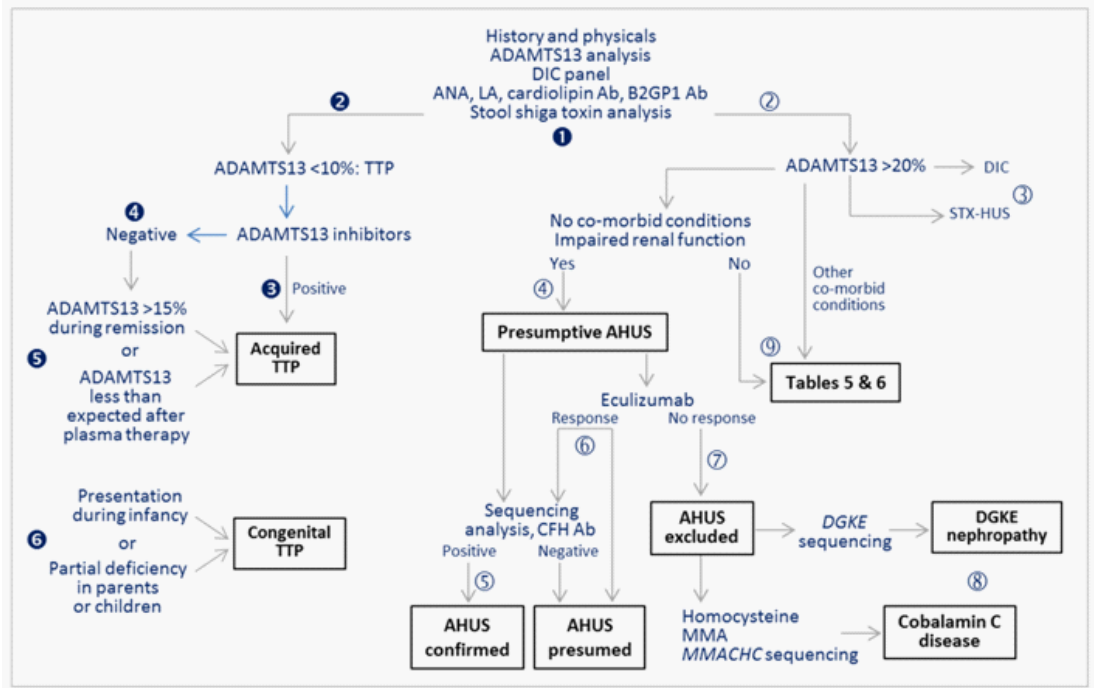
When plasma ADAMTS13 activity is >20% without plasma or blood transfusions (②), TTP is excluded. Coagulation profile and stool shiga toxin analysis should provide diagnostic information for DIC and STX-HUS (③).

Patients with renal dysfunction by none of the comorbid conditions listed in Tables 3 and 4 are presumed to have AHUS (④). The diagnosis of AHUS is confirmed when sequence analysis detects mutations of regulators (e.g., complement factor H, CD46, complement factor I, and thrombomodulin) or activators (e.g., complement factor B, C3) of the alternative complement pathway, or ELISA detects antibodies of complement factor H (⑤).

For patients with active complications such as thrombocytopenia, deteriorating renal function or extra-renal manifestations, anti-complement therapy with eculizumab before the diagnosis is confirmed can be life-saving. Rapid responses to anticomplement treatment support the diagnosis of AHUS (⑥), whereas lack of responses to the treatment is a strong evidence against the diagnosis of aHUS (⑦), unless the patient has other concurrent causes of these complications.

When AHUS is excluded, further analysis for mutations of *Diacylglycerol Kinase Epsilon (DGKE)* or *Methyl Malonic Aciduria Cblc Type with Homocystinuria (MMACHC)* are indicated for DGKE nephropathy or cobalamin C disease (⑧).

**Figure 1:** A scheme of systemic approach to the differential diagnosis of MAHA and thrombocytopenia.



When gene sequencing and complement factor H antibody tests are not available, the finding of thrombotic microangiopathy in kidney biopsy supports the diagnosis of AHUS after other causes of the pathology are excluded (Table 3).

## NEW CONCEPTS IN THE MANAGEMENT OF TTP

The conventional treatment for acquired TTP is plasma exchange. While this treatment has reduced the risk of death from greater than 90% to approximately 10%, it does not alter the course of ADAMTS13 inhibitors that may cause subsequent relapses, which occurs at least once in nearly 90% of the cases in 7 years [6]. Corticosteroids, cyclophosphamide or azathioprine are not very effective in decreasing the risk of relapse and not infrequently are associated with serious complications.

Preemptive rituximab therapy, immediately after the diagnosis of acquired TTP is confirmed, may decrease the risk of early relapses [29]. Nevertheless, the duration of the effect does not last. Relapses continue to occur, most commonly after one or more years. Late relapses may be prevented by a strategy of repeated rituximab therapy guided by serial plasma ADAMTS13 activity levels [6,30].

Hereditary TTP responds to plasma infusion at approximately 5-7.5 ml/kg every 2-3 weeks. Most patients require maintenance therapy to prevent unpredictable but potentially serious

complications such as strokes, which may occur abruptly and unexpectedly, and inconspicuous but progressive deterioration of renal and intellectual functions.

## **NEW THERAPIES UNDER INVESTIGATION**

New therapies under or deserve investigation include aptamer (e.g., ARC1779 [31,32]) or nanobody (e.g., caplacizumab [33,34]) blockers of VWF-platelet binding, which, by immediate suppression of microvascular thrombosis, may potentially be life-saving for cases with severe complications but may create a false impression of remission; disulfide bond reducing agents such as N-acetylhomocysteine that at high concentrations decrease the size of VWF multimers [35-39]; and proteasome inhibitors such as bortezomib that deplete long-lasting plasma cells [40-45].

Plasmin cleaves VWF and decreases its size and platelet-aggregating activity and thus may control VWF-platelet thrombosis in TTP [46]. Nevertheless, plasmin also inactivates ADAMTS13 [47,48] and may increase the risk of bleeding. Further investigation is needed to determine whether activation of the fibrinolytic system will prove to be effective and safe for the treatment of TTP.

## **NEW CONCEPTS IN THE MANAGEMENT OF AHUS**

Historically, AHUS has been treated as TTP with plasma exchange or plasma infusion, supplemented with corticosteroids, immunosuppressive drugs such as cyclophosphamide and rituximab and even splenectomy. With such treatment, more than 50% of the cases die or develop end stage renal disease by one year [9,49]. Based on our current knowledge in its pathogenesis, the efficacy of plasma exchange or infusion for AHUS is likely to vary depending on the underlying molecular defects. The use of corticosteroids, rituximab and splenectomy for AHUS is unfounded, with exception of possible benefit for patients with antibodies of complement factor H.

Anticomplement therapy with eculizumab has been shown to be highly effective in suppressing complement activation [50]. It effectively replaces plasma exchange in patients who require the treatment to prevent relapses. It also induces remission in patients who do not respond to plasma exchange. Many patients gladly find their kidney function improving with anticomplement therapy.

In patients with thrombocytopenia or extra-renal complications of abnormal vascular permeability, anticomplement therapy is followed by resolution of thrombocytopenia and steady alleviation of the extra-renal complications by one week [51]. For patients with labile hypertension, the blood pressure often stabilizes by two weeks of treatment. Thus, when eculizumab is instituted for presumptive AHUS, lack of expected responses practically excludes the diagnosis of AHUS and the indication of continuing anticomplement therapy, unless the patient happens to have other concurrent causes of these complications. Examples for lack of response include pseudo-thrombocytopenia due to in vitro platelet clumping, concurrent plasma exchange, and inadequate



suppression of complement activation. Adequacy of complement suppression can be assessed by total complement test (CH50) [52].

In contrast to the rapid resolution of thrombocytopenia and extra-renal complications, improvement of renal function following blockage of complement activation may be quite slow, spanning over the course of several months to more than a year. Because kidney injury may be irreversible, lack of renal function improvement with anticomplement therapy does not exclude the diagnosis of AHUS.

Patients who have evidence of disease activity such as headache, anorexia, nausea, abdominal pain or increasingly unstable blood pressures before each biweekly dose of treatment obviously require the treatment more frequently and the treatment needs to continue indefinitely. Anticomplement therapy should also be continued indefinitely for patients who have frequent relapses of disease activity or progressive renal function deterioration without the treatment.

Historically, some patients of AHUS have stable kidney function and no relapses for years after one episode of acute renal failure, MAHA and thrombocytopenia. For such patients, indefinite long-term maintenance treatment would be costly and unnecessarily expose the patients to the risk of fulminant meningococcal sepsis in association of anticomplement therapy. Nevertheless, identifying these patients a priori remains a challenge.

One way to meet this challenge is a strategy of slow tapering of the treatment and close monitoring for early symptoms, signs and laboratory findings of relapses. Candidate patients for tapering should be asymptomatic and have stable renal functions with anti-complement therapy. Serious complications of AHUS do not occur abruptly without warning symptoms. With a strategy of prompt anti-complement therapy as soon as there is evidence of incipient relapse, serious complications can be prevented.

## **RESISTANCE OF C5 VARIANTS TO INACTIVATION BY ECULIZUMAB**

Certain variants of complement C5 (e.g., R885H and R885C) may interfere with its binding with eculizumab. Eculizumab is ineffective for PNH patients with such C5 variants [53]. It is reasonable to assume that eculizumab may also be ineffective for AHUS patients with such C5 variants. Studies are ongoing to identify alternatives of eculizumab whose effectiveness is not affected by the genetic variations [54,55].

## **CONCLUSIONS**

Since the discovery of ADMTS13 deficiency in TTP and defective regulation of the alternative complement pathway in AHUS, it has become apparent that the syndrome of MAHA and thrombocytopenia may result from a group of etiologically or mechanistically diverse disorders. With a new scheme of disease classification, it is now possible to approach the diagnosis of the syndrome of MAHA and thrombocytopenia in a rational manner. Furthermore, it is also recognized that TTP or AHUS may present without MAHA or thrombocytopenia. Correct diagnosis without delay is an essential first step for successful management of these serious diseases.

## References

1. Hickey F, Hickey E, Summar KL. Medical update for children with Down syndrome for the pediatrician and family practitioner. *Adv Pediatr.* 2012; 59: 137-157.
2. Lejeune J, Gautier M, Turpin R. Study of somatic chromosomes from 9 mongoloid children. *C R Hebd Seances Acad Sci.* 1959; 248: 1721-1722.
3. Gasser C, Gautier E, Steck A, Siebenmann RE, Oechslin R. Hemolytic-uremic syndrome: bilateral necrosis of the renal cortex in acute acquired hemolytic anemia. *Schweiz Med Wochenschr.* 1955; 85: 905-909.
4. Habib R. Pathology of the hemolytic uremic syndrome. In: Bernard S. Kaplan, Richard S. Trompeter, Joel L. Moake, eds. New York: Marcel Dekker, Inc.; 1992; 315-353.
5. Karmali MA, Steele BT, Petric M, Lim C. Sporadic cases of haemolytic-uraemic syndrome associated with faecal cytotoxin and cytotoxin-producing *Escherichia coli* in stools. *Lancet.* 1983; 1: 619-620.
6. Tsai HM. Acquired thrombotic thrombocytopenic purpura. In: Rodgers, GM (ed): *ADAMTS13: Biology and Disease*, chapter 6, pp. 91-128. Springer. 2015.
7. Tsai HM, Lian EC. Antibodies to von Willebrand factor-cleaving protease in acute thrombotic thrombocytopenic purpura. *N Engl J Med.* 1998; 339: 1585-1594.
8. Levy GG, Nichols WC, Lian EC, Foroud T, McClintick JN, McGee BM, et al. Mutations in a member of the ADAMTS gene family cause thrombotic thrombocytopenic purpura. *Nature.* 2001; 413: 488-494.
9. Fremeaux-Bacchi V, Fakhouri F, Garnier A, Bienaime F, Dragon-Durey MA, Ngo S, et al. Genetics and outcome of atypical hemolytic uremic syndrome: a nationwide French series comparing children and adults. *Clin J Am Soc Nephrol.* 2013; 8: 554-562.
10. Tsai H-M. Thrombotic thrombocytopenic purpura, hemolytic uremic syndrome and related disorders. In: *Wintrobe's Clinical Hematology*, 13/e, Chapter 48. JP Greer, J Foerster, G M Rodgers, F Paraskevas, B Glader, DA Arber & RT Means Jr (eds). Lippincott Williams & Wilkins. 2013.
11. Tsai HM. Microangiopathic hemolytic anemia. In: *Reference Module in Biomedical Sciences*, Elsevier 2014.
12. Iacopino P, Pucci G, Arcese W, Bosi A, Falda M, Locatelli F, et al. Severe thrombotic microangiopathy: an infrequent complication of bone marrow transplantation. Gruppo Italiano Trapianto Midollo Osseo (GITMO). *Bone Marrow Transplant.* 1999; 24: 47-51.
13. Jodele S, Licht C, Goebel J, Dixon BP, Zhang K, Sivakumaran TA, et al. Abnormalities in the alternative pathway of complement in children with hematopoietic stem cell transplant-associated thrombotic microangiopathy. *Blood.* 2013; 122: 2003-2007.
14. Veyradier A, Brivet F, Wolf M, Boyer-Neumann C, Obert B, Girma JP, et al. Total deficiency of specific von Willebrand factor-cleaving protease and recovery following plasma therapy in one patient with hemolytic-uremic syndrome. *Hematol J.* 2001; 2: 352-354.
15. Noris M, Bucchioni S, Galbusera M, Donadelli R, Bresin E, Castelletti F, et al. Complement factor H mutation in familial thrombotic thrombocytopenic purpura with ADAMTS13 deficiency and renal involvement. *J Am Soc Nephrol.* 2005; 16: 1177-1183.
16. Sanchez-Luceros A, Farias CE, Amaral MM, Kempfer AC, Votta R, Marchese C, et al. von Willebrand factor-cleaving protease (ADAMTS13) activity in normal non-pregnant women, pregnant and post-delivery women. *Thromb Haemost.* 2004; 92: 1320-1326.
17. Lattuada A, Rossi E, Calzarossa C, Candolfi R, Mannucci PM. Mild to moderate reduction of a von Willebrand factor cleaving protease (ADAMTS-13) in pregnant women with HELLP microangiopathic syndrome. *Haematologica.* 2003; 88: 1029-1034.
18. Brunelli SM, Meyers KE, Guttenberg M, Kaplan P, Kaplan BS. Cobalamin C deficiency complicated by an atypical glomerulopathy. *Pediatr Nephrol.* 2002; 17: 800-803.
19. Lemaire M, Fremeaux-Bacchi V, Schaefer F, Choi M, Tang WH, Le Quintrec M, et al. Recessive mutations in DGKE cause atypical hemolytic-uremic syndrome. *Nat Genet.* 2013; 45: 531-536.
20. Cornec-Le GE, Delmas Y, De PL, Doucet L, Ogier H, Benoist JF, et al. Adult-onset eculizumab-resistant hemolytic uremic syndrome associated with cobalamin C deficiency. *Am J Kidney Dis.* 2014; 63: 119-123.
21. Martinelli D, Deodato F, Dionisi-Vici C. Cobalamin C defect: natural history, pathophysiology, and treatment. *J Inher Metab Dis.* 2011; 34: 127-135.
22. Amraoui F, Bos S, Vogt L, van den Born BJ. Long-term renal outcome in patients with malignant hypertension: a retrospective cohort study. *BMC Nephrol.* 2012; 13: 71.
23. van den Born BJ, Honnebier UP, Koopmans RP, van Montfrans GA. Microangiopathic hemolysis and renal failure in malignant hypertension. *Hypertension.* 2005; 45: 246-251.

24. Sinclair RA, Antonovych TT, Mostofi FK. Renal proliferative arteriopathies and associated glomerular changes: a light and electron microscopic study. *Hum Pathol.* 1976; 7: 565-588.
25. Tsai HM. Does anticomplement therapy have a role in the management of malignant hypertension? *J Clin Hypertens (Greenwich)*. 2016; 18: 359-360.
26. Tsai HM. Thrombotic thrombocytopenic purpura and the atypical hemolytic uremic syndrome: an update. *Hematol Oncol Clin North Am.* 2013; 27: 565-584.
27. Denny KJ, Woodruff TM, Taylor SM, Callaway LK. Complement in pregnancy: a delicate balance. *Am J Reprod Immunol.* 2013; 69: 3-11.
28. Salmon JE, Heuser C, Triebwasser M, Liszewski MK, Kavanagh D, Roumenina L, et al. Mutations in complement regulatory proteins predispose to preeclampsia: a genetic analysis of the PROMISSE cohort. *PLoS Med.* 2011; 8: e1001013.
29. Westwood JP, Webster H, McGuckin S, McDonald V, Machin SJ, Scully M. Rituximab for thrombotic thrombocytopenic purpura: benefit of early administration during acute episodes and use of prophylaxis to prevent relapse. *J Thromb Haemost.* 2013; 11: 481-490.
30. Tsai HM. New Concepts of Thrombotic Thrombocytopenic Purpura and a Strategy to Prevent its Relapse. *J Hematol Thrombo Dis.* 2014; 2: 157.
31. Cataland SR, Peyvandi F, Mannucci PM, Lammle B, Kremer Hovinga JA, Machin SJ, et al. Initial experience from a double-blind, placebo-controlled, clinical outcome study of ARC1779 in patients with thrombotic thrombocytopenic purpura. *Am J Hematol.* 2012; 87: 430-432.
32. Jilma-Stohlawetz P, Gorczyca ME, Jilma B, Siller-Matula J, Gilbert JC, Knobl P. Inhibition of von Willebrand factor by ARC1779 in patients with acute thrombotic thrombocytopenic purpura. *Thromb Haemost.* 2011; 105: 545-552.
33. Bartunek J, Barbato E, Heyndrickx G, Vanderheyden M, Wijns W, Holz JB. Novel antiplatelet agents: ALX-0081, a Nanobody directed towards von Willebrand factor. *J Cardiovasc Transl Res.* 2013; 6: 355-363.
34. Peyvandi F, Scully M, Kremer Hovinga JA, Cataland S, Knobl P, Wu H, et al. Caplacizumab for Acquired Thrombotic Thrombocytopenic Purpura. *N Engl J Med.* 2016; 374: 511-522.
35. Chen J, Reheman A, Gushiken FC, Nolasco L, Fu X, Moake JL, et al. N-acetylcysteine reduces the size and activity of von Willebrand factor in human plasma and mice. *J Clin Invest.* 2011; 121: 593-603.
36. Li GW, Rambally S, Kamboj J, Reilly S, Moake JL, Udden MM, et al. Treatment of refractory thrombotic thrombocytopenic purpura with N-acetylcysteine: a case report. *Transfusion.* 2014; 54: 1221-1224.
37. Shortt J, Opat SS, Wood EM. N-Acetylcysteine for thrombotic thrombocytopenic purpura: is a von Willebrand factor-inhibitory dose feasible in vivo? *Transfusion.* 2014; 54: 2362-2363.
38. Cabanillas G, Popescu-Martinez A. N-Acetylcysteine for Relapsing Thrombotic Thrombocytopenic Purpura: More Evidence of a Promising Drug. *Am J Ther.* 2015.
39. Rottenstreich A, Hochberg-Klein S, Rund D, Kalish Y. The role of N-acetylcysteine in the treatment of thrombotic thrombocytopenic purpura. *J Thromb Thrombolysis.* 2016; 41: 678-683.
40. Shortt J, Oh DH, Opat SS. ADAMTS13 antibody depletion by bortezomib in thrombotic thrombocytopenic purpura. *N Engl J Med.* 2013; 368: 90-92.
41. Mazepa MA, Raval JS, Moll S, Ma A, Park YA. Bortezomib induces clinical remission and reduction of ADAMTS13 inhibitory antibodies in relapsed refractory idiopathic thrombotic thrombocytopenic purpura. *Br J Haematol.* 2014; 164: 900-902.
42. van Balen T, Schreuder MF, de Jong H, van de Kar NC. Refractory thrombotic thrombocytopenic purpura in a 16-year-old girl: successful treatment with bortezomib. *Eur J Haematol.* 2014; 92: 80-82.
43. Yates S, Matevosyan K, Rutherford C, Shen YM, Sarode R. Bortezomib for chronic relapsing thrombotic thrombocytopenic purpura: a case report. *Transfusion.* 2014; 54: 2064-2067.
44. Patel PP, Becker J, Freyer C, Griffiths E, Thompson JE, Wang ES. Rituximab-refractory thrombotic thrombocytopenic purpura responsive to intravenous but not subcutaneous bortezomib. *Transfusion.* 2016.
45. Patriquin CJ, Thomas MR, Dutt T, McGuckin, Blombery PA, Cranfield T, et al. Bortezomib in the treatment of refractory thrombotic thrombocytopenic purpura. *Br J Haematol.* 2016.
46. Hoirisch-Clapauch S, Nardi AE. A role for tissue plasminogen activator in thrombotic thrombocytopenic purpura. *Med Hypotheses.* 2014; 83: 747-750.
47. Crawley JT, Lam JK, Rance JB, Mollica LR, O'Donnell JS, Lane DA. Proteolytic inactivation of ADAMTS13 by thrombin and plasmin. *Blood.* 2005; 105: 1085-1093.

48. Feys HB, Vandeputte N, Palla R, Peyvandi K, Deckmyn H, Lijnen HR, et al. Inactivation of ADAMTS13 by plasmin as a potential cause of thrombotic thrombocytopenic purpura. *J Thromb Haemost.* 2010; 8: 2053-2062.
49. Noris M, Caprioli J, Bresin E, Mossali C, Pianetti G, Gamba S, et al. Relative role of genetic complement abnormalities in sporadic and familial aHUS and their impact on clinical phenotype. *Clin J Am Soc Nephrol.* 2010; 5: 1844-1859.
50. Legendre CM, Licht C, Muus P, Greenbaum LA, Babu S, Bedrosian C, et al. Terminal complement inhibitor eculizumab in atypical hemolytic-uremic syndrome. *N Engl J Med.* 2013; 368: 2169-2181.
51. Tsai HM, Kuo E. Eculizumab therapy leads to rapid resolution of thrombocytopenia in atypical hemolytic uremic syndrome. *Adv Hematol.* 2014; 295323.
52. Jodele S, Fukuda T, Vinks A, Mizuno K, Laskin BL, Goebel J, et al. Eculizumab therapy in children with severe hematopoietic stem cell transplantation-associated thrombotic microangiopathy. *Biol Blood Marrow Transplant.* 2014; 20: 518-525.
53. Nishimura J, Yamamoto M, Hayashi S, Ohyashik K, Ando K, Brodsky AL, et al. Genetic variants in C5 and poor response to eculizumab. *N Engl J Med.* 2014; 370: 632-639.
54. Weston-Davies W, Westwood JP, Nunn M. Phase 1 clinical trial of novel complement C5 inhibitor coversin. *Molecular Immunology.* 2013; 56: 264.
55. Ueda Y, Osato M, Weston-Davies W, Nunn MA, Hayashi S, Nishimura JI, et al. Coversin blocked in vitro hemolysis in an eculizumab-resistant PNH patient with the C5 polymorphism (c.2654G>A). *Blood* 2015.